

Neurological Examination

Made Practical

Kareem M. Al-Tameemi

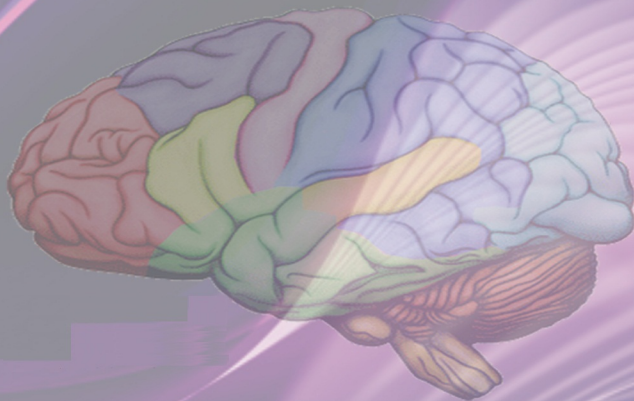
ISBN 978-0-9864331-1-5

BM-Publisher

USA

Email:

bmpublisher@bmpublisher.net



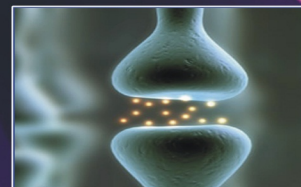
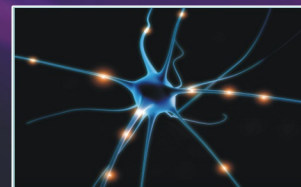
Kareem M. Al-Tameemi

Made Practical

Neurological Examination

Neurological Examination

Made Practical



Kareem M. Al-Tameemi

Dedication

This text book is dedicated to my family, to all colleagues working in neurology, the souls of all victims of violence in Iraq and lastly to our patients to whom this book is worked up

Acknowledgement

I would like to thank my wife Zahra Jawad for her continuous help in providing comfortable atmosphere for writing this book, my son yehia, last year student in the college of pharmacy and my daughter hadeel third year student in the same college for their help in preparing some pictures and diagrams for this book.

All rights reserved. No part of this publication may be reproduced or transmitted in any form or by any means, electronically or mechanically, including photocopying, recording or any information storage or retrieval system, without the prior permission from the BM-publisher

Whilst the information in this book is believed to be true and accurate at the date of going to press, the BMpublisher cannot accept any legal responsibility or liability for any errors or omissions that may be made

Neurological Examination Made Practical® is a registered trademark of the BM-Publisher, Inc

ISBN 978-0-9864331-1-5

BM-Publisher 

Dearborn, Michigan 48126

USA

Email: bmpublisher@bmpublisher.net

Neurological Examination Made Practical

Kareem M. Al-Tameemi, MD, FIBN

Fellowship of Iraqi Board in Neurology

Assistant professor of Neurology

College of Medicine, Karbala University, Iraq

First Edition

2015

ISBN 978-0-9864331-1-5

BM-Publisher

Email: bmpublisher@bmpublisher.net

Contents

Chapter 1: Examination of higher cerebral function	
1-1 The level of consciousness.....	1
1-2 Memory.....	6
1-3: Orientation	12
1-4: Judgment and Reasoning	15
1-5: The Language	16
1-6: The Integrative sensory function	27
1-7: The Integrative motor function	33
1-8: The Primitive Reflexes	36
Chapter 2: Examination of the cranial nerves	
2-1: The first cranial nerve	38
2-2: The second cranial nerve	41
2-3: The Third, Fourth, and the six cranial nerves	58
2-4: The Fifth cranial nerve	82
2-5: The seventh cranial nerve	88
2-6: The eighth cranial nerve	95
2-7: The ninth and tenth cranial nerve	102
2-8: The eleventh cranial nerve	111
2-9: The twelfth cranial nerve	115
Chapter 3: Neurological examination of the upper and lower limbs	
3-1: Examination of motor system	118
3-1-1: Inspection	118
3-1-2: Examination of the muscle tone	128
3-1-3: Examination of the power	131
3-1-4: Examination of the reflexes	135
3-1-5:Co-ordination	142
3-2: Examination of sensory system	147
3-2-1: Principles of sensory system examination	147
3-2-2: Methods of examination of sensory system	150
3-2-3: The common patterns of abnormal sensation	154
3-3: Examination of Gait	157
Chapter 4: The examination and localization of neurological weakness	
4-1: Upper motor neuron lesion	162
4-2: Lower motor neuron lesion	165
4-3: Neuromuscular transmission disorders	168
4-4: Myopathic disorders	169
Chapter 5: The examination of unconscious patient	
5-1: Coma definition	170
5-2: Purpose of examination	170
5-3: Method of examination	170

5-3-1: General examination	174
5-3-2: Systemic examination	173
5-3-3: Neurological examination	174
5-4: Results of examination	181
5-4-1: Supratentorial structural lesion	182
5-4-2: Subtentorial structural lesion	185
5-4-3: Metabolic encephalopathy	186
Chapter 6: Cerebral lobes examination	
6-1: Frontal lobe examination	187
6-2: Temporal lobe examination	188
6-4: Parietal lobe examination	188
6-4: Occipital lobe examination	189
Chapter 7: Autonomic nervous system examination	
7-1: Method of examination	192
7-2: Results of examination	193
Bibliography	195
Index	196

CHAPTER ONE

EXAMINATION OF HIGHER CEREBRAL FUNCTIONS

It includes examination of the following functions:

- 1-Level of consciousness
- 2-Memory
- 3-Orientation
- 4-Judgment & reasoning
- 5-Language
- 6-Integrative sensory functions
- 7-Integrative motor functions
- 8-Primitive reflexes

1-1: Level of Consciousness

Method of examination

1-Verbal stimulation

If the patient is awake, talk to him, test his orientation for time, place and person (to exclude confusion) and ask him to obey simple commands like lift your hand, open your mouth, open your eye (to exclude Wernicke's aphasia), look up, look down, and look at the tip of your nose (to exclude lock in syndrome).

- I. If the patient is in a sleepy state try to wake him by tactile stimulation or by calling his name. If no response to tactile or verbal stimulation proceed to the next stage of stimulation which is painful stimulation.

2. Painful (noxious) stimulation

It is done by supraorbital or sternal pressure (rubbing the sternum vigorously by the knuckle of the hands), pinching the side of the neck or inner parts of the arm or thighs or pressure on the nail bed, and by noticing the patient's responses (eye, verbal and motor) to these stimuli (both verbal and noxious) we can roughly estimate the level of consciousness and its changes from hour to hour.

Interpretation of the results

1. Normal consciousness: The patient is aware of himself and environment, he is a wake, alert, with eyes open at rest and unless there is deafness or language disorder, verbal stimulation results in appropriate verbal responses.
2. Impaired consciousness: Characterized by defect of arousal. There is infinite gradation of altered consciousness but the terms drowsiness, stupor, and coma usefully describe the three major stages which can be clinically recognized.

Drowsiness

It is a sleepy state from which the patient can be aroused to a state of complete wakefulness and cooperation by verbal or tactile stimuli, but he tends to sink into sleep again if stimulation ceases. This condition is common in high brainstem disturbances directly or indirectly and in drug toxicity.

Stupor

It is a sleeplike state from which the patient can be aroused by vigorous or repeated stimulation (Verbal, tactile, or painful), he answer questions appropriately or inappropriately, just to fall a sleep again. No satisfactory co-operation is obtained. This condition is caused by disease or compression of the upper brain stem, or by bilateral cerebral dysfunction (anoxic, toxic, traumatic or infective).

Coma

It is a sleep like state from which the patient cannot be aroused. The patient is not aware of his internal or external needs. The eyes are typically closed and do not open spontaneously. The patient doesn't speak and there is no purposeful movement of the face or limbs. Verbal stimulation produce no response, painful stimulation may also produce no response or may elicit non-purposeful reflex movement mediated through the spinal cord or brainstem

pathways. Coma results from a disturbance in the function of either the brainstem reticular activating system above the midpons or both cerebral hemispheres. Coma is best evaluated by Glasgow coma scale, Table (1).

3. Turbidity of consciousness

Confusion

It is inability to think with customary speed and clarity, with incoherent speech associated with disorientation and impairment of the memory. Confusion most often results from a process that influences the brain globally such as toxic or metabolic disturbances or dementia. Confusion also may results from any condition that leads to drowsiness or stupor. Important differential diagnosis includes:

- I. Wernicke's aphasia.
- II. Psychosis.
- III. Non-dominant hemisphere lesions.
- IV. Subdural hematoma.
- V. Disorders of memory or visuospatial orientation.

Delirium

It is a confusional state plus agitation and aggressive behavior, commonly associated with hallucination and delusion plus autonomic over activity and motor abnormalities like (tremor, myoclonus and asterexis). A delirious like state is commonly caused by infective and toxic state and in delirium tremens of alcoholism.

4. Dissociated consciousness

It means dissociation between consciousness and motor performance, where the patient performs programmed action that you can not resist and after which the patient can not remember it. This is called automatism. It is commonly occur in partial complex epilepsy and fugue state of hysteria.

Important related syndromes

1. Persistent vegetative state:

This condition means preserved autonomic and brain stem function without cognition, some patients who sustained severe coma due to cerebral hypoxia or ischemia or structural brain lesion may regain wakefulness but not awareness. After one month, this condition is called persistent vegetative state. Such patients have spontaneous eye opening and sleep-wake cycle which differentiate them from comatose patients.

2. Locked-in syndrome (Akinetic mutism)

Such patient appears comatose but is awake and alert, although they are mute and quadriplegic. The diagnosis is made by noting that voluntary eye opening, vertical eye movements, ocular convergence, or some combination of these midbrain mediated movements is preserved. During the examination of any apparently comatose patient, the patient should be told to open your eyes, look up, look down and look at the tip of your nose, to elicit such movements. The cause of this syndrome is due to functional transection of the brain stem below the midpons level. The usual causes are pontine infarction, hemorrhage, central pontine myelinolysis, tumor or encephalitis.

3. Psychogenic unresponsiveness:

We must always think of this possibility in any seemingly comatose patient, in whom general, physical and neurological examination is normal. This condition may occur in schizophrenia (catatonic type), conversion disorders, somatization disorders and malingering.

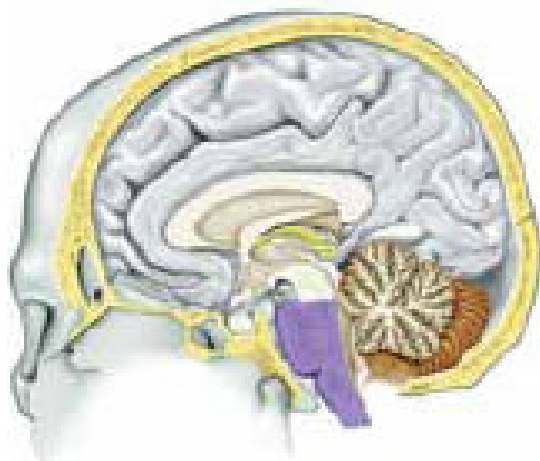
4. Brain death:

We must always think of this possibility in any patient who is deeply comatose and maintained on a ventilator because spontaneous breathing had been inadequate or had ceased. Preconditions for considering a diagnosis of brain death and tests for confirming it is beyond the scope of this book.

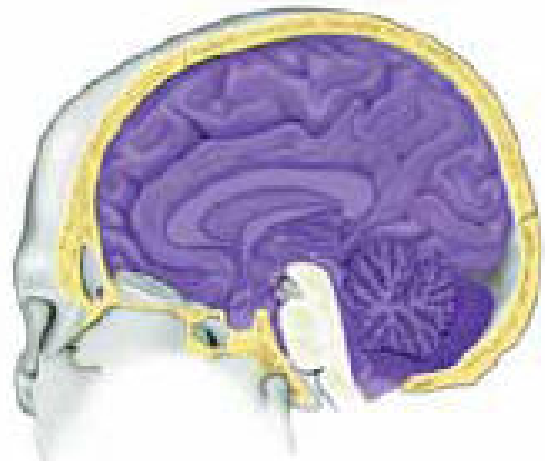
Pictures at page 5 give the anatomical site of the above lesions.

Table 1. The Glasgow Coma Scale.

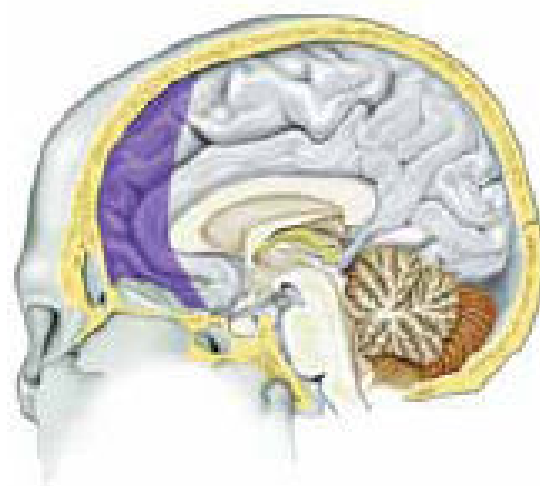
Eye opening		Verbal response		Motor response	
Spontaneous	4	Oriented	5	Obeying	5
To speech	3	Confused	4	Localizing	4
To pain	2	Inappropriate	3	Flexing	3
None	1	Incomprehensible	2	Extension	2
		None	1	None	1



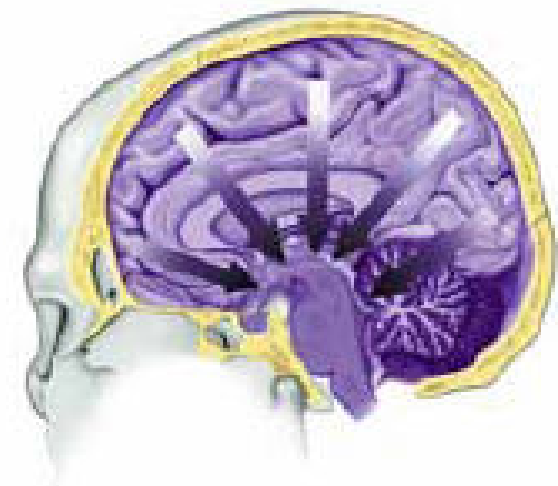
Lesion causing locked-in syndrome



Lesion causing apallic syndrome



**Bifrontal lesion
(causing akinetic mutism)**



**Lesion causing death (total
absence of brain function)**

1-2: Memory

Tests of memory

Memory is assessed clinically by testing immediate recall, recent memory and remote memory, which correspond roughly to registration, storage and retrieval, respectively.

1. Immediate recall (registration)

- a. Digit number: ask the patient to repeat a random series of numbers; most normal adult can repeat a series of seven numbers forward and five numbers backward without difficulty.
- b. Babcock's sentence: "there is one thing a nation must have to be rich and great, and that is a large, secure supply of wood", or any other sentence and ask the patient to repeat this sentence directly after the examiner.

2. Recent memory (short term memory)

- a. Ask the patient about events that occurred before minutes to hours, like what was your breakfast.
- b. Ask the patient to recall the names of three objects repeated to the patient before three minutes.
- c. Non-verbal testing: ask the patient to select an object previously shown to him from a group of objects. This test is especially suitable for patients with expressive aphasia.

3. Remote memory (long term memory)

- a. Ask the patient about historical, personal or geographical events.
- b. Ask the patient to give association or connection between these events. The questions must be appropriate for the patient, that some one of comparable cultural and educational background can be assumed to know, for example (when was your marriage? And what was the color of your neck tie?)

Introduction

Memory is the ability to register, store, and finally retrieve information. Short term memory can be impaired by diseases which affect the medial temporal lobe bilaterally while long term memory is usually a manifestation of diffuse cortical disease. The functional components of memory are:

1. Registration: which is the ability to receive information through the appropriate primary sensory areas as well as the corresponding association cortex, ablation of the primary auditory and the adjacent association auditory cortices will abolish the immediate memory of auditory type. The duration of recall is a matter of seconds.
2. Storage: it is the process by which new information and tasks are learned. It is the function of the limbic structures including the hippocampus and related structures like the mamillary bodies and the dorsomedial nuclei of the thalamus. Stored memory is reinforced by repetitions and emotional significance. Short term memory may be recalled for minutes to hours.
3. Retrieval: this is the ability to project previously learned information. It can be recalled months or years after it has been stored. It reflects the integrity of the whole cerebral cortex and the subcortical structures in addition.

Amnesia

It is a memory disorder which can be classified into

1. Isolated amnesic syndromes.
2. Non-isolated that is part or one feature of global cognitive disorder which can occur in two conditions.
 - I. Acute confusional state
 - II. Dementia
3. Psychogenic amnesia

1- Isolated amnesic syndromes

These syndromes are usually characterized by the following features:

- I. In acute amnesic syndromes there is usually impairment of short term memory and registration.

- II. Confabulation: Some patients may attempt to fill in gaps in memory with false recollections.
- III. Retrograde amnesia for a variable period preceding the event may be present, but this period shrinks as the condition improves.
- IV. In chronic amnesic syndromes long term memory is also affected but to a lesser extent than short term. Registration is intact.
- V. Site of lesion is bilateral damage to hippocampus, and related structures such as the dorsomedial nucleus of the thalamus or mammillary body.
- VI. Other features of amnesic syndrome are usually related to the site of lesions other than that of memory.

Causes of isolated amnesic syndrome

Acute

- I. Head trauma.
- II. Hypoxia or ischemia.
- III. Bilateral posterior cerebral artery occlusion.
- IV. Transient global amnesia (TGA).
- V. Alcoholic blackouts.

Chronic

- I. Alcoholic Korsakoff amnesic syndrome.
- II. Post encephalitic amnesia.
- III. Brain tumor.
- IV. Paraneoplastic limbic encephalitis.

2-Amnesia accompanying acute confusional state

In this condition, attention is impaired, resulting in impairment of registration and inability to form new memories. Decrease in the level of consciousness is the chief complaint. Those patients are usually in a sleepy state and disoriented for time and place.

3-Amnesia accompany dementias

Dementias are usually chronic, steadily, progressive and the level of consciousness is not impaired. Amnesia is usually associated with impairment of

other spheres of cognition like language, parietal lobe functions (construction, left-right orientation), frontal lobe or diffuse cerebral cortical functions (Judgment, abstraction and the ability to perform previously learned skills as shown in pictures at page 11. The mini mental status examination provides a useful bed side screening test when dementia is suspected, Table (2).

Causes of Dementia

For better approach and management of the patient the causes of dementias are best divided into reversible and irreversible.

1. Often reversible:

- ☞ Infectious: e.g. Neurosyphilis.
- ☞ Deficiency states: e.g. .vitamin B1 or B12, folic acid.
- ☞ Toxins: drugs, heavy metals.
- ☞ Metabolic: e.g. hypothyroidism, hypoglycemia, hypocalcaemia, Cushing syndrome, liver or renal failure.
- ☞ Trauma: e.g. subdural haematoma.
- ☞ Others: hydrocephalus, anoxia, tumors.

2. Irreversible

- ☞ Hereditary: e.g. Huntington's chorea
- ☞ Prion disease: e.g. Greutzfeldt-Jakob disease
- ☞ Non metastatic manifestation of malignancy: e.g. bronchial carcinoma
- ☞ Others: Alzheimer's or pick's disease.

N.B The commonest causes of dementia in order of frequency include.

I. Alzheimer

II. Dementia with lewy bodies.

III. Vascular dementia (multi infarct Dementia).

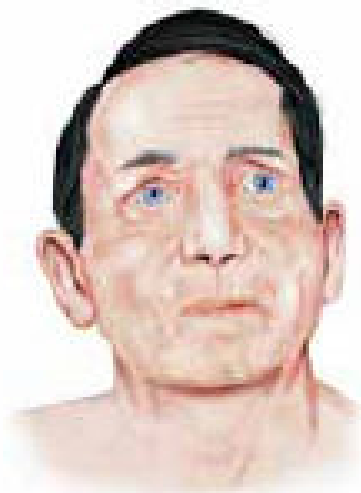3- Psychogenic amnesia

In this condition subjective and emotionally charged memories are more affected than is recalling of objective facts and events. In organic amnesia the reverse is true. Isolated loss of memory for personal identity in awake and alert person is virtually diagnostic of a psychogenic problem.

Table 2. Minimental status examination

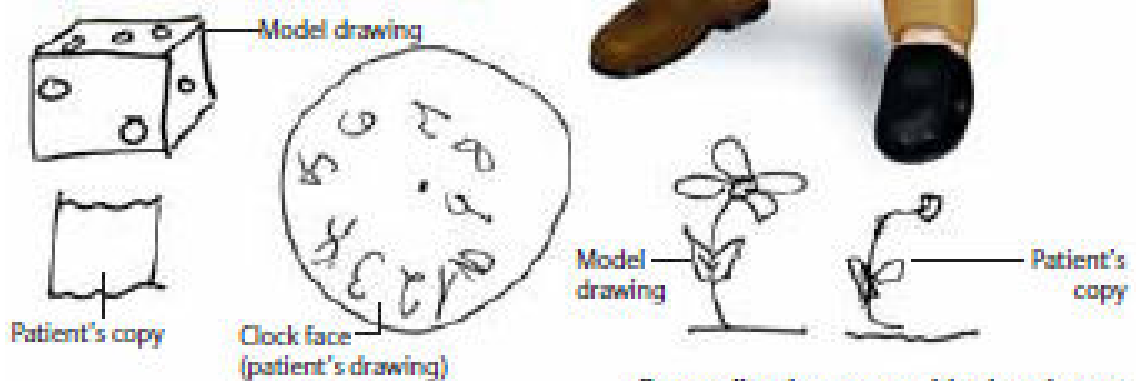
Item.	Points
Orientation	
Time(1 point each for year, season, month, date, and day of the week)	5
Place(1 point each for state, country, city, building and Floor or room)	5
Registration.... repeat names of three objects (1point per object	3
Attention and calculation.	
Serial 7s or spell “world” Backward (1 point per subtraction or letter	5
Recall names of three objects repeated previously(1point per object)	3
Language	
Repeat “no islands or butts”	1
Read and follow “close your eyes)	1
Write a complete sentence.	1
Construction... Copy two interesting pentagons.	1
Total	30

A total of less than 24 should generally lead to more detailed investigation of the possibility of dementia, although norms vary to some extent with age and education.



Loss of cognitive function

- **Memory impairment** (short- and long-term memory)
- **Impairment of other higher cortical functions** (abstraction, judgment, arithmetic, aphasia, apraxia, agnosia, attention)
- **Personality change**
- **Loss of social and occupational skills**



Rohkamm, Color Atlas of Neurology @ 2004 Thieme.

1-3 Orientation

Orientation is usually tested in three dimensions.

1. Time – Ask the patient about (day, date, month, year), what time of the day is it?
2. Place – Ask where he is now (room, building, town, country), what floor is it on?
3. Person – Ask the patient about his (name, age, work, address) also ask him about the relative's names who are around his bed?

Interpretation of results

Orientation is usually impaired in acute confusional states, and it must be tested early to assess the level of consciousness. If the level of consciousness is normal disorientation is usually occur in amnestic syndromes and psychiatric disorders. The latter condition is suggested when there is disorientation for personal identity rather than place and time.

Common causes of acute confusional states are listed in table (3).and partial list of drugs that can produce it is provided in table (4).

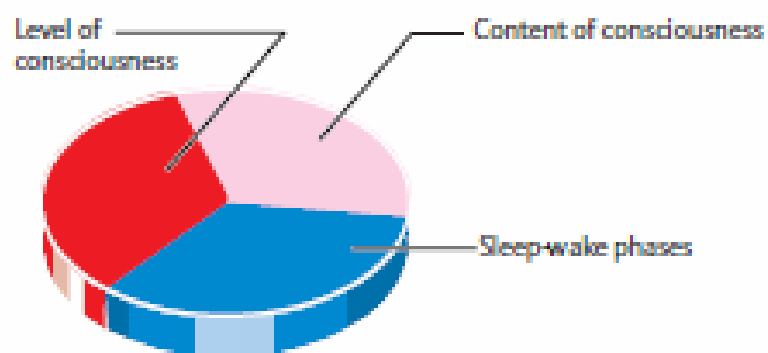
Table 3. Common Causes of acute Confusional States

Causes	Examples
1-Metabolic disorders:	Ethanol intoxication or withdrawal, Sedative drug intoxication or withdrawal, opioids, anticholinergic Hypothyroidism, hyperthyroidism. hypoglycemia, hyperglycemia hyponatremia, hypocalcemia, hypercalcemia hepatic encephalopathy, Reye's syndrome, uremia, dialysis disequilibrium, pulmonary encephalopathy ,organ transplantation Bacterial meningitis, viral encephalitis, tuberculous meningitis, leptomenigeal metastases, AIDS, others Hypertensive encephalopathy, subarachnoid hemorrhage,vertebrobasilar ischemia, right (non dominant) hemisphere infarction, SLE, DIC,TTP Concussion, Intracranial hemorrhage Post ictal state, Complex partial seizure
Drugs	
Endocrine disorder	
Nutritional disorders	
Organ system failure	
2-Infectious and Noninfectious.	Concussion, Intracranial hemorrhage Post ictal state, Complex partial seizure
3-Vascular disorders	
4-Head trauma	
5-Seizure	


Table 4. Therapeutic drugs associated with acute confusional states

List (A)	List (B)
Acyclovir , Disulfiram	Amantadine , Ergot alkaloids
Aminocaproic acid , Ethanol	Amphetamines , Ganciclovir
Anticholinergic , Hallucinogens	Anticonvulsants , Isoniazid
Antidepressants , Ketamine	Antihistamines , Levodopa
Antipsychotics , Lidocaine	Baclofen , Methylxanthines
Barbiturates	Benzodiazepines , Opioids
B-blocker , Penicillin	Cephalosporins , Quinacrine
Chloroquine , Quinidine	Cocaine , Quinine
Corticosteroids , Salicylate	Cyclosporine , Selegiline
Digoxin , Thyroid hormones	Non steroidal anti-inflammatory

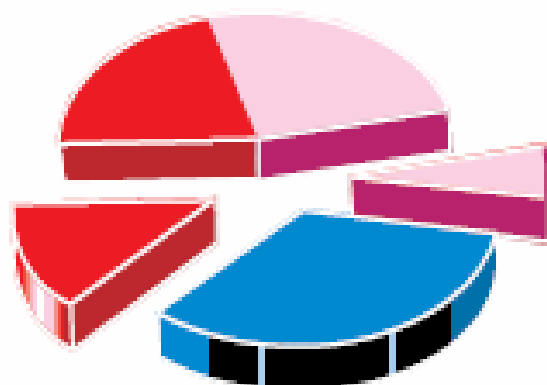
Pictures at page 14, from Rohkamm, color atlas of neurology, illustrate the mechanism of normal consciousness, apallic syndrome, acute confusion, disturbances of arousal and stupor state,




Normal state of consciousness




Apallic syndrome



Acute confusion



Disturbance of arousal (hypersomnia)



Somnolence, stupor

1-4 Judgment and Reasoning

This important category of cognitive abilities must be included in every attempt to evaluate the mental status, it includes at least testing of Abstraction, calculation and general behavior.

1. Abstraction and calculation

Method of examination

- I. Proverb interpretation: Ask the patient to explain proverb or fable.
- II. Similarities and dissimilarities ask the patient to describe similarities and differences between groups of object (orange and a ball, child and dwarf, etc...)
- III. 100-7 test: subtraction of serials 3's or 7's from 100 is a good test of calculation and concentration.

2. General behavior: It includes mood, hallucinations, delusions and other abnormalities of behavior like attitude, manner of dress...etc

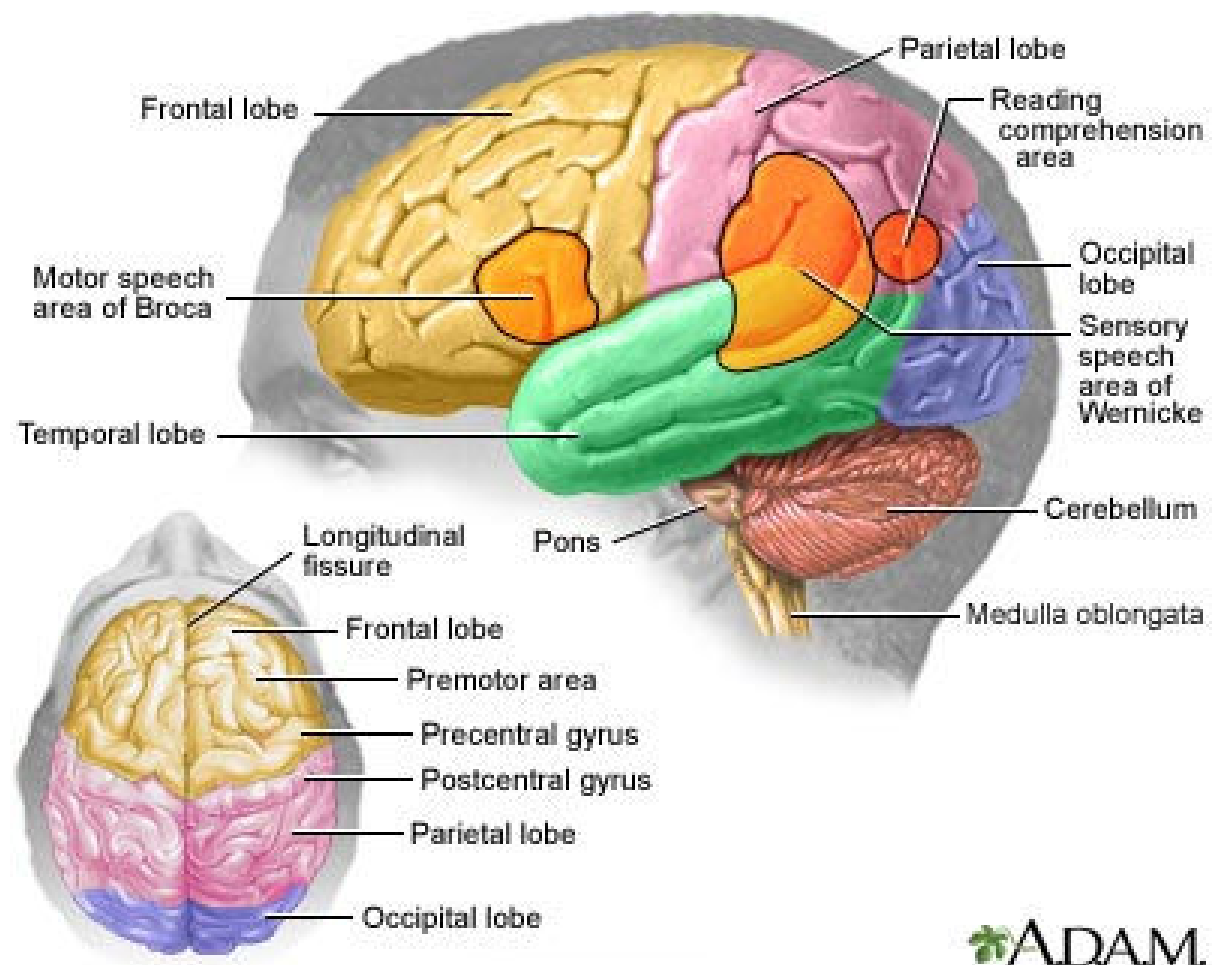
Interpretation of the results

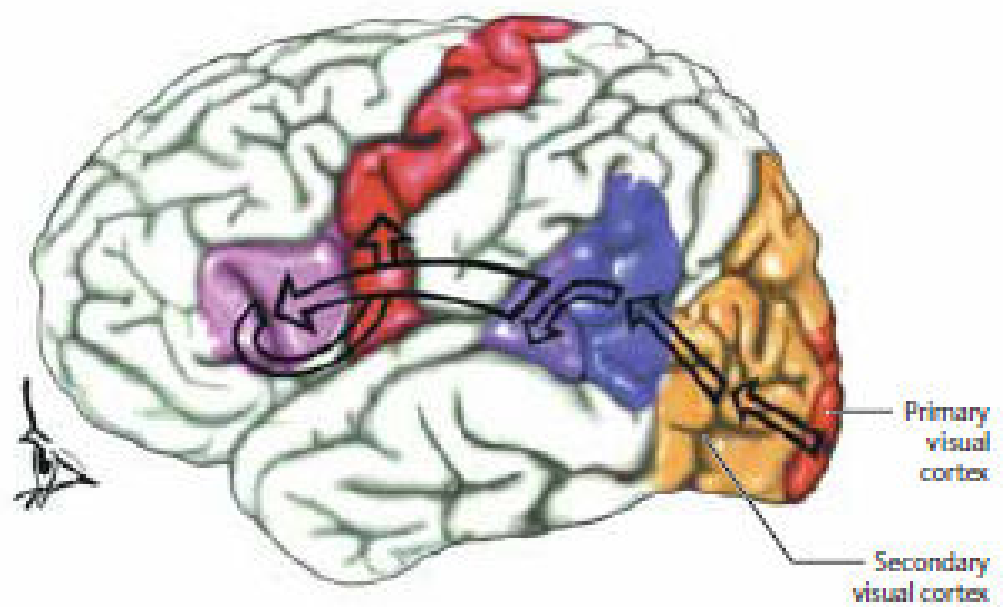
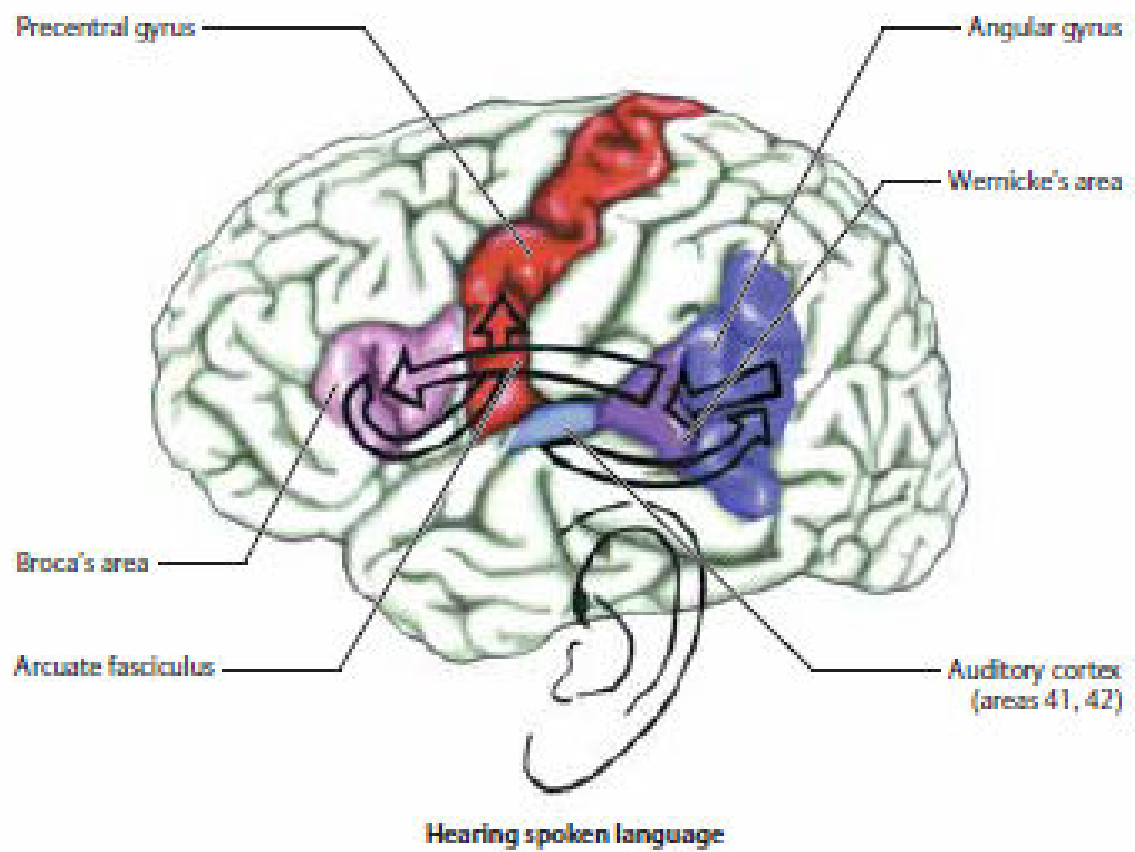
Abnormalities of these tests can help to distinguish between organic and psychiatric disease. Abstraction and calculation are usually impaired in Dementia. Visual hallucinations are common in acute confusional states, while auditory hallucinations and fixed delusions are most common with psychiatric disorders.

Demented patients may be apathetic, inappropriately elated or depressed, and their moods can fluctuate. If the examination is other wise normal, early dementia can easily be confused with depression.

1- 5: Language Examination

The essential elements of language are comprehension, expression, repetition, naming, reading and writing. The important preliminary information needed for correct assessment of Language are nationality, native Language, educational level, mental state, handedness and the previous ability to read or write. The different anatomical areas controlling language are well illustrated below at pages 16 and 17.





Methods of Examination

* Language is examined in six aspects

1. Comprehension to spoken Language

Ask the patient to obey simple commands for example (Lift your hand, Close your eye, Open your mouth, Point to certain objects around the room). If he did the previous tests easily then ask him to obey more complex commands for e.g. (lift your hand and close your eyes).

2. Expression

Ask the patient to talk about his illness without interruption from his family and note the following important parameters of his speech.

I. Fluency: Is he fluent or non-fluent?

If the patient is severely non-fluent, communication is still feasible by asking the patient to answer by yes or no. if he is totally mute and the comprehension is relatively spared communication is done by eyes movement.

II. Awareness: Is he aware of his deficit or his speech?

III. Errors: Is he doing mistakes like, paraphasias, Neologism, perseverations and circumlocutions

Paraphasia: these are of two types:-

Literal: which means substitution of a syllable within the word e.g. the grass is greel

Verbal: It means substitution of one word for another e.g. the grass is blue

- Neologism. It means appearance of phonemes, syllable or words that are not part of the language e.g. the grass is grumps.
- Perseveration: The patient involuntarily repeats the same words or acts just after it has been employed.
- Circumlocution: The patient uses a long sentence to overcome failure to find particular word.

3. Repetition

Ask the patient to repeat a complex phrase, and if he fails ask him to repeat simpler one or even a single word.

4. Naming

Ask the patient about the names of common objects, if he fails to give the right names, ask him to choose the correct one from a list of alternatives. Use about twenty objects before deciding that no abnormality exists. Patients with true nominal aphasia usually fail to give the correct names of three objects out of twenty.

5. Reading

- I. Ask the patient to read words, then sentences, then longer passages.
- II. Ask him to read and obey a written command, this will link the motor and sensory side.
- III. Patient with alexia is unable to understand a written speech.

6. Writing

- I. Test the ability to write to dictation then ask him to construct a sentence or to compose a piece about his job, town or weather.
- II. Patient with agraphia may be able to write his name or address but unable to construct a sentence.

Aphasia: It means a disturbance of the ability to use language, whether in speaking, writing or comprehension.

Clinical varieties of aphasia

The preceding systematic examination of language will usually enable one to disclose the following types of dysphasia.

1. Broca's aphasia.
2. Wernicke's aphasia.
3. Total or global aphasia.
4. Dissociative or (Disconnection) syndromes such as:
 - I. Conduction aphasias.
 - II. Word deafness (Auditory verbal agnosia).
 - III. Word blindness (visual verbal agnosia or alexia).
 - IV. Pure word mutism.
 - V. Transcortical aphasias.

5. Anomic aphasia

6. Agraphias

Broca's aphasia

- Speech is non-fluent even to the point of mutism in extreme examples.
- Relative preservation of comprehension.
- Poor, repetition, reading and writing.
- Phrases length is abbreviated and many of the small words (article, prepositions and conjunctions) are omitted giving the speech a telegraphic character (so-called agrammatism).
- Other important features of Broca's aphasia includes: verbal stereotypy, apraxia of speech, limbs and right facio- brachial palsy.
- Site of lesion is usually includes Broca's area plus deep white matter between Broca's area and motor cortex, the anterior insula, frontal- parietal operculum, and adjacent cerebrum..
- Causes: embolic infarction in the territory of upper main (rolandic) division of the middle cerebral artery is probably the most frequent cause of vascular lesion. Other causes include: thrombosis, tumor, sub cortical hypertensive hemorrhage, traumatic hemorrhage and seizure.

Wernicke's aphasia

- Speech is Fluent and paraphasic.
- Comprehension is impaired for both spoken and written language.
- Impairment of repetition, naming and writing.
- The patient is unaware of his deficit or his own errors. Fluent paraphasic speech may be entirely incomprehensible (Jargon aphasia).
- Site of Lesion: Posterior perisylvian region.
- Causes: embolic (less often thrombotic) occlusion of the lower division of the left middle cerebral artery. Other rare causes include Hemorrhage. Tumor, abscess and extension of a small putaminal or thalamic hemorrhage.

Total or global aphasia

- All aspects of language are affected, but they can utter few syllable such as, ah, or cry, shout or moan. In other words, they are not mute.
- With the passage of time, some degree of comprehension of language may return, and the patient is left with severe Broca's aphasia.
- Varying degree of right hemiplegia, hemianesthesia, and homonymous hemianopia almost invariably accompanying global aphasia of vascular origin.
- Site of lesion: large part of the language area (sensory and motor parts).
- Causes: the lesion is usually due to occlusion of the left internal carotid or middle cerebral artery. But it may be caused by tumor, hemorrhage or other lesion and it may occur transiently as a post-ictal effect.

Dissociative syndromes

Conduction aphasia

- Speech is fluent and paraphasic but comprehension is relatively spared, thus distinguishing it from Wernick's aphasia.
- Site of the lesion: arcuate fasciculus which connect the sensory and motor areas of speech.
- Causes: embolic occlusion of the ascending parietal or posterior temporal branch of the middle cerebral artery, but other causes like neoplasm, or trauma in the region may produce the same syndrome.

Pure word deafness

- Impairment of auditory comprehension and repetition and an inability to write to dictation.
- Spontaneous speech, writing, and reading are normal, thus distinguishing this disorder from the classic Wernick's aphasia.
- Site of lesion: bilateral in the middle third of the superior temporal gyri, in a position to interrupt the connection between primary auditory cortex and the association areas. In rare cases unilateral lesions have been localized in this part of the dominant temporal lobe.

- Causes: Embolic occlusion of small branch of the lower division of the middle cerebral artery.

Alexia

The patient can not understand the written speech. It can be divided into 2 types:

1. Alexia without agraphia (pure word blindness): The patient is able to speak, understand spoken language, he can write both spontaneously and to dictation but can not understand or copy the written words.
Site of the lesion: left occipital cortex and splenium of the corpus-callosum so both visual cortices are separated from the language area of the left hemisphere.
2. Alexia with agraphia: The patient can not read or write spontaneously. This is part of Gerstman syndrome i.e. right-left confusion, acalculia, finger agnosia, anomia in addition to alexia and agraphia.
Site of the lesion: angular gyrus or the subjacent white matter.
In such cases, there is no right homonymous hemianopia. The entire collection of symptoms is sometimes called the Syndrome of angular gyrus.

Pure word mutism

- The patient loses all capacity to articulate or he has a severe slurring of speech.
- Comprehension, reading and writing are normal from the onset.
- After recovery, the language shows neither loss of vocabulary nor agrammatism, or there may be mild dysarthria (hence cortical dysarthria), anomia, and paraphasic substitutions.
- The most notable feature of this type of speech disorder is its transience, and within few weeks or months, language is returned to normal.
- Site of the lesion: The anatomic site has not been determined precisely. In a few postmortem cases, reference is made to a lesion in Broca's area.
- Causes: Commonly vascular.

Transcortical aphasia

These dysphasias characterized by normal repetition due to pathology which isolate the intact motor and sensory language areas from the rest of the cortex of the same hemisphere. They usually follow water-shed infarction between middle, anterior and posterior cerebral arteries, as a result of prolonged hypotension, carbon monoxide poisoning or other forms of anoxia. They are of three types:

1. transcortical sensory aphasia

It is similar to Wernicke's aphasia (fluent, paraphasic speech) but the repetition is remarkably preserved.

Site of the lesion: posterior parietal-occipital region, posterior and inferior to Wernick's area. This location explains the frequent concurrence of transient visual agnosia and hemianopia.

Causes: Water-shed infarction that disconnects the auditory language area from the referent centers.

2. transcortical motor aphasia

The speech is non-fluent speech with relative preservation of comprehension, but the repetition is strikingly intact.

Site of the lesion: anterior to Sylvain fissure but superior to Broca's area (anterior isolation syndrome).

Causes: it occur in 2 clinical situations:

- Mild, partially recovered Broca's aphasia.
- In states of abulia and a kinetic mutism with frontal lobe damage, for the same region.

3. Echolalia

The speech is non fluent, comprehension is poor but repetition is still possible leading to persistent echolalia which means involuntary repetition of words or phrases spoken by someone else without the intention of doing so, and without understanding their meanings.

Site of the lesion: Infarction of the whole area surrounding the perisylvian regions, and the latter becomes isolated from other cortical area. The lesion lies in the temporo-parietal region.

Causes: Water-shed infarction due to sudden hemodynamic disturbances of perfusion.

Anomic aphasia

- Disorder confined to naming of people and objects.
- Other language functions (reading, writing spelling...etc) being adequate.
- Recall of the names of letters, digits, and other printed verbal material is almost invariably preserved, and immediate repetition of a spoken name is intact. That the deficit is principally one of the naming is shown by the patient correct use of the object and usually by an ability to point to the correct object on hearing or seeing the name and to choose the correct name from a list. The patient's understanding of what is heard or read is normal.
- Site of the lesion: Lower temporal lobe in a place which interrupt connections between sensory language areas and the hippocampal regions concerned with learning and memory.
- Causes: Mass lesions e.g. tumors, herpes encephalitis or an abscess are the most frequent causes; as they enlarge, a contra lateral upper quadrantic visual field defect or a Wernick's aphasia is added. Occasionally, anomia appears with lesions due to occlusion of the temporal branches of the posterior cerebral artery.
- N.B.: some degree of anomia is part of every type of language disorders, but when the anomia is the most notable aspect of language difficulty, the term anomic aphasia is employed, so anomia may part of the following speech disorders:
 - I. Transcortical motor aphasia.
 - II. Gerstmann syndrome.
 - III. Alzheimer disease.
 - IV. Old age.

V. Finally anomic aphasia may be the only residual abnormality after partial recovery from Wernick's aphasia, conduction, transcortical sensory, or rarely Broca's aphasia.

5. Agraphia

Writing is disturbed in all types of aphasia except in 2 conditions (pure word mutism and pure word blindness). Pure agraphia as the initial and sole disturbance of language function is very rare, but such case can occur in lesion between the angular gyrus and the motor area, but sometimes be anterior or posterior to this.

The notion of a specific center for writing in the posterior part of second frontal convolution (extner's writing area) has questioned by some aphasiologist, however, case of pure dysgraphia have been reported due to hematoma located in the Centrum semiovale beneath the motor parts of frontal cortex.

Types of agraphia or dysgraphia

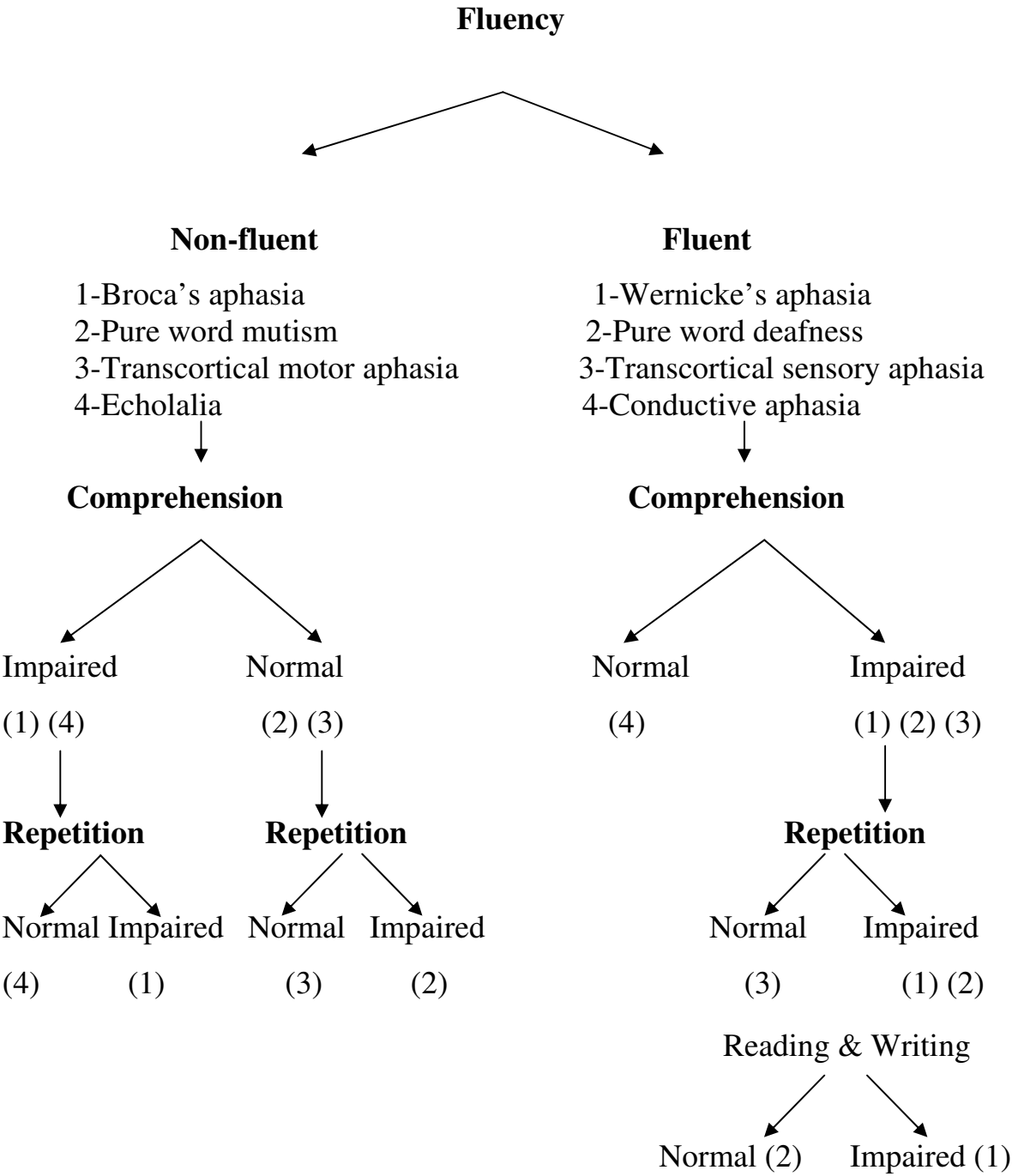
1. Aphasic agraphia-- Language formulation is defective, spelling and grammatical errors are prominent.
2. Constructional agraphia-- In this circumstance, letter and words are formed clearly enough but are wrongly arranged on the page. Words may be superimposed, written diagonally, in haphazard arrangement, or from right to left. With right parietal lobe lesions, only the right half of the page is used.
3. Apraxic agraphia—here language formulation is correct and the spatial arrangements of words are respected, but the hand had lost its skills in forming letters and words. The patient is uncertain about how to held pen and how to apply it on paper.

Schematic approach of aphasic patient

This can be done by listening to the patient fluency, testing comprehension and lastly asking the patient to repeat certain phrases and sentences (table-5-). Other disorders of speech which include, agraphias,

anomias, and alexia, can be tested by examining writing, naming and reading respectively.

Table (5) schematic approach of aphasia



1- 6: Integrative Sensory Functions

Sensory integrative disorders from parietal lobe lesions are manifested by misperception of or inattention to sensory stimuli on the contra lateral side of the body, when the primary sensory modalities are intact. Patients with parietal lobe lesions may exhibit the following signs:

1. Asteriognosis.
2. Agraphesthesia.
3. Absence of two point's discrimination.
4. Allesthesia (failure of localization of touch).
5. Disorders of body scheme or image.
6. Agnosia.

1-Astereognosis:

The patient can not identify, by touch, an object placed in his hand.

Methods of examination

Ask the patient to close his eyes; the object is placed first into the hand suspected of abnormality. If he fails or take a long time to decide, it should then be placed into the other hand, for comparison of the accuracy and speed of response. Tested object must be familiar and large enough for a weak hand to feel.

Result of examination

Patient with astereognosis can not identify any detail of the object at all. He is unaware that anything has been placed in his hand. Its particular value in localization arise when, though other form of sensation (touch, position) are normal or only slightly affected, yet there is astereognosis, the lesion responsible then lies in the parietal lobe.

2-Agraphesthesia

The patient is unable to recognize letters or numbers written on the skin with a blunt point.

Method of examination

Ask the patient to close his eyes, and letters or numerals are written on the palm, anterior aspect of the forearm, thigh or lower leg. Clear figures should be used first, and if correct, the more difficult, can be used as a finer test.

Result of examination

If peripheral sensation is normal, agraphesthesia indicates parietal lobe lesion.

3-Absence of two point discrimination

This is an inability to differentiate between a single and two simultaneously applied adjacent, but separated, stimuli that can be distinguished by a normal person.

Method of examination

Ask the patient to close his eyes, and touch the pulp of his finger firmly with the two point's discriminator, starting with them far apart, and approximating them until the patient begins to make errors. The threshold is thus determined and the other hand can be compared. The same test can be carried on the dorsum of the foot.

Result of examination

The normal ability to distinguish the two points from one varies in different parts of the body. On the fingers it should be possible at less than 5 mm separation, but on the dorsum of the foot, separation of even 5 cm may be still normal. Impairment of the two point discrimination test indicates parietal lobe lesion when light touch only slightly affected or normal and no signs of severe dorsal column disease is present.

4-Allesthesia (failure of localization of touch)

Method of examination

Ask the patient to close his eyes and then he is touched on some point of the body with examiners finger or a pin. He is then asked to indicate the point touched with his own forefinger.

Result: the significance of this test is the same as for agraphesthesia and two point discrimination

5-Asomatognosia (Disorders of body scheme or images).

Methods of examination

- 1-Ask the patient the patient which is his right and left hand or leg.
- 2-Ask him to point to different fingers of his right and left hands, make the questions more difficult gradually.
- 3-Try to know whether: the patient is aware about his disability or not. If he seems unaware, draw his attention specifically to the weak limb and ask him to explain his inability to move it.
- 4-Check for sensory inattention which means that a visual, tactile or auditory stimulus is perceived when applied alone to the side contralateral to the lesion, but not when stimuli are applied bilaterally and simultaneously.

Results of Examination


A-Unilateral asomatognosia, include the following types:

- 1-Amorphosynthesis.The patient in this condition ignore or neglect the opposite side of the body and the extratrapersonal space of this side. This condition represents the full extent of this disturbance, which in lesser degree consist only of tactile and visual extinctions.
- 2-Anosognosia.The patient here is unaware, neglect or even deny the opposite side of his body which is usually the left side in a right handed patient.
- 3-Sensory inattention. In this condition the neglect of one side may be present, but not in the gross degree described above, it is then necessary to present to the patient simultaneous and bilateral stimulation of one of the common senses in order to detect the defect which includes visual, auditory, and tactile inattention.

Site of Lesion

The lesion responsible for the various forms of unilateral asomatognosia lies in the cortex and white matter of the superior parietal lobule, but may extend into the post central gyrus,frontal motor areas,

Temporal and occipital lobes account for some of the associated abnormalities. Rarely, a deep lesion of the ventrolateral thalamus and juxtaposed white matter of the parietal lobe will produce contra lateral neglect. Unilateral asomatognosia is seven times as frequent with right (non-dominant) parietal lesion as with left sided ones.



B-Bilateral asomatognosia (gerstmann syndrome of finger agnosia, left-right confusion, acalculia and agraphia) .This syndrome provides the most striking example of bilateral asomatognosia and, it is due to a left or dominant parietal lobe lesion. The characteristic features are

- I.Inability to designate or name the different fingers of the two hands.
- II. Confusion of the right and the left sides of the body.
- III.Inability to write
- IV.Inability to calculate.

5-Agnosia

It means failure to recognize some object or sound when the sense by which it is normally recognized remains intact.

Examination of Agnosias

1-Visual Agnosia

Methods of examination

- 1-Show the patient a number of common small objects and asks him about their names and uses. If he fails to do so allow him to feel the object in a hand in which the sensation is normal and ask him the same question.
- 2-Ask him about the names of different colors.
- 3-Ask him lastly to walk toward a particular point, having placed some chairs in the way and observe whether he is able to find his way to the correct place and around the obstruction.

Results of examination

- 1-Visual object agnosia--The patient is unable to name or describe the use of the object shown ,but he is able to identify them by touch.Patient with nominal aphasia will be able to find the exact name whichever sense is used ,also he is usually able to describe the uses of the object.
- 2-Visual color agnosia --The patient is unable to identify colors, this is often associated with object agnosia, the site of lesion for both condition lies in the dominant occipital hemisphere.

3-Visual space agnosia -- The patient is unable to find his way around an obstruction or to find his way to a given point .It is most marked in bilateral posterior –inferior parietal lesions but a unilateral lesion can cause agnosia for one –half of the space, so that the patient will turn always to the opposite side and is liable to return to the point of starting .This is most clearly demonstrated when the non dominant hemisphere is affected.

2-Tactile Agnosia

Methods of examination

- 1-Ask the patient to close his eyes and then place a number of common objects in turn in one or other hand and ask him to name them ,to describe their shape, size and texture and to indicate their use
- 2-If he fails to do so, allow him to look at them and see if he is able to know them.

Results of examination

In tactile agnosia the patient is able to describe the object regarding their size, shape and texture, but unable to give it's name or it's use, and particularly if on seeing it he is then able to name it .The site of the lesion is in the contra lateral parietal lobe (supramarginal gyrus)

3-Auditory Agnosia

Method of examination

Ask the patient to close his eyes and to identify sounds made by friction, striking a match.etc.

Results of examination

In auditory agnosia, the patient is unable to recognize these sounds, but can recognize the objects on sight or touch, and as there is often associated word deafness, it may be necessary, to write out construction, the site of the lesion is in the posterior part of the temporal convolution of the dominant hemisphere.

1-7: Integrative Motor Function (Apraxia)

Apraxia: It is the inability to perform previously learned skills, despite intact motor, sensory and co-ordination functions.

Methods of Examination

- 1-Ask the patient to put out his tongue, blow out match, close eyes, and show his teeth, for (facial-oral apraxia)
- 2-Make fist, wave goodbye, point, imitates use of comb, tooth brush and scissor for ideomotor apraxia.
- 3-Ask the patient to light cigarette for ideational apraxia.
- 4-Note how he manipulates buttons, or studs, how he takes off his coat and jackets and puts them on again, for dressing apraxia.
- 5-Commands and copy cube, clock, house, flower, star, matches, etc. if this appears difficult do it for him and ask him to copy it, for constructional apraxia.

Results of Examination

Four types of apraxia are usually recognized

- 1-Ideomotor apraxia:** the patient performs automatic acts normally, such as shaking hands, blowing his nose, etc, and is able to formulate the idea of an act and to describe how it should be done, but he is unable to do it correctly on command. This is probably the commonest type of apraxia, the basic disturbance is an inability to imitate an act involving the use of objects.
- 2-Ideational apraxia:** the formulation of the method carrying out the whole of complex act is defective, although the execution of different parts of the complete act may be normal. The best example is lightening cigarette. The basic problem here is inability to use object properly, and there is no problem with imitation. In clinical practice, ideomotor and ideational apraxia frequently coexist
- 3-Constructional apraxia:** the patient is defeated by attempts to make design with, for instance, matches, either spontaneously or by copying; often in writing he cramps every thing into one small corner of the paper.

4-Dressing apraxia: the patient becomes hopeless when he try to dress and undress, put his clothes on the wrong way round ,or may be quite unable to start the necessary motions. This defect, which is also present if ideational apraxia is present, may be found entirely by its self.

Localization of Lesions Causing Apraxia

Lipman who introduced the term of apraxia in 1990 suggested that a planned or commanded action is normally developed in the parietal lobe of the dominant hemisphere, where visual, auditory, and somasthetic information is integrated.

***Lesions producing ideomotor apraxia**

A-In the dominant supramarginal gyrus should produce bilateral apraxia.

b-Between this gyrus and the left motor cortex should produced right sided apraxia in the right handed people.

c-In the corpus callosum should produced left sided apraxia, but this site is questionable in so far as left limb apraxia has not been observed in patients with lesions or surgical section confined to the anterior third of corpus callosum. More commonly left limb apraxia is usually seen in left frontal lobe lesion, and includes broca's area, the left motor cortex and deep underlying white matter. Clinically there is a motor speech disorder, a right hemi paresis and apraxia of the non-paralyzed hand i.e. sympathetic apraxia.

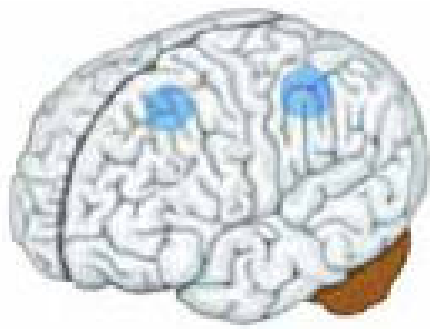
*** Lesions producing constructional apraxia.**

It occurs in angular gyrus lesions of either hemisphere, but when isolated is usually from non-dominant parietal lesion.

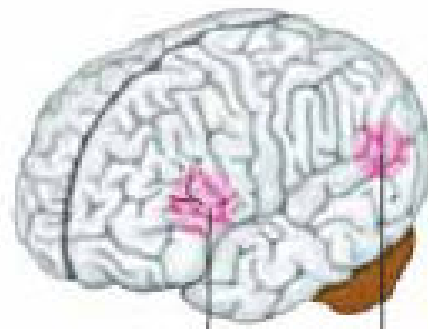
*** Lesions producing dressing apraxia.**

Usually occurs in non-dominant posterior parietal lobe lesion.

Causes of apraxia; vascular and degenerative lesions are more often responsible than neoplasm. Lesions that cause different types of apraxias are shown below at page 35.



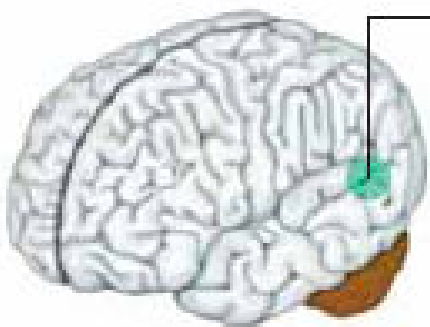
Sites of lesions causing agraphia



Anterior alexia


Central alexia

Topography of lesions in alexia



Numerical
alexia/agraphia,
anarithmia

Sites of lesions causing acalculia



Ideomotor apraxia



Dressing apraxia



Lid-opening apraxia

1- 8: Primitive Reflexes

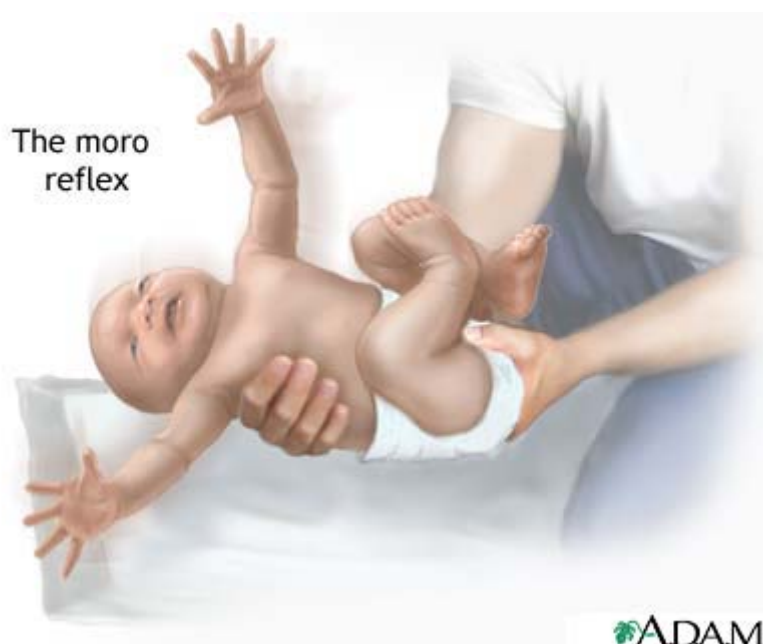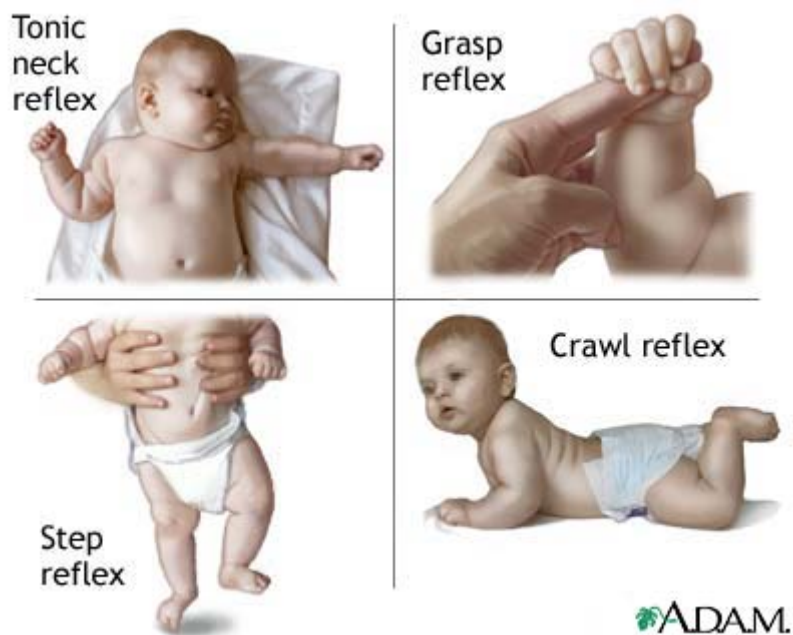
Methods of Examination

- 1-The palmer grasp reflex. It is elicited by stroking the skin of the patient's palm with the examiner's fingers. If the reflex is present, the patient's fingers close around those of the examiner. The force of the patient's grasp increase when the examiner attempts to withdraw the fingers, and the patient be unable to voluntarily release the grasp.
- 2-The plantar reflex. It consists of flexion and adduction of the toes in response to stimulation of the sole of the foot.
- 3-The palmomental reflex. It is elicited by scratching along the length of the palm of the hand and results in contraction of the ipsilateral chin (mentalis) and perioral (orbicularis) muscle.
- 4-The suck reflex. It consists of involuntary sucking movements following the stimulation of the lips.
- 5-The snout reflex. It is elicited by gently tapping the lips and results in their protrusion
- 6-The rooting reflex. Stimulation of the lips causes them to deviate towards the stimulus.
- 7-The glabellar reflex. It is elicited by repetitive tapping on the forehead. Normal person blink only in response to the first several taps. Persistant blinking is abnormal response (myerson's sign)
- 8-The avoiding response. It consists of a tendency for the patients hand to move away from palmer or dorsal stroking or touch. It is usually evoked by stimuli on the ulnar surface of the hand. It is found in patients with contra lateral parietal lobe disease, or lesions in its connections.

Interpretation

A number of reflexes that are present in infancy and subsequently disappear may be released again by frontal lobe dysfunction in later life. It is presumed that such release results from loss of cortical inhibition of these primitive reflexes (frontal release signs) which include palmer& planter grasps,

palmomental, suck, snout, rooting and glabellar reflexes. Although these reflexes are often seen in both acute confusional state and dementia, many of them can also occur in normal elderly adult. An exception to this is grasp and suck reflexes which invariably indicate frontal lobe lesion. In infancy the presence of these reflexes is used as part of the developmental assessment. See pictures below.



CHAPTER TWO

EXAMINATIONS OF THE CRANIAL NERVES

2-1: The First Cranial Nerve (The olfactory nerve)

Function

It carries sensation of smell from the nasal mucosa to the olfactory bulb. The stimuli then pass through the olfactory tract and roots, especially the lateral root, running to the peri-amygdaloid, and pre-piriform areas of the cortex and probably not to the hippocampus as usually thought (Figure 1).

Purposes of the tests:

- 1- To determine whether any impairment of smell is unilateral or bilateral.
- 2- To determine whether this impairment is due to local nasal disorders or due to olfactory (neural) lesion.

Methods of examination

- 1- Several tubes are prepared containing substances which are familiar and non-irritant like coffee, peppermint, tobacco, almond, oil of lemon, ...etc.
- 2- The patient must then compress each nostril in turn and by sniffing through the other, show that the airway is open.
- 3- The test odor is then placed under one nostril while the other is compressed, and the patient after closing his eyes is told to take two good sniffs. Then he will be asked:

- a. If he can smell any thing and
- b. If he can identify the odor.

The test is then repeated using the second nostril and he is asked:

- c. If the odor is the same in each nostril.

After an interval to allow the odor to disperse, the test is then repeated with two other odors and the patient must be asked another additional questions that:

- d. If he can distinguish the different odors.

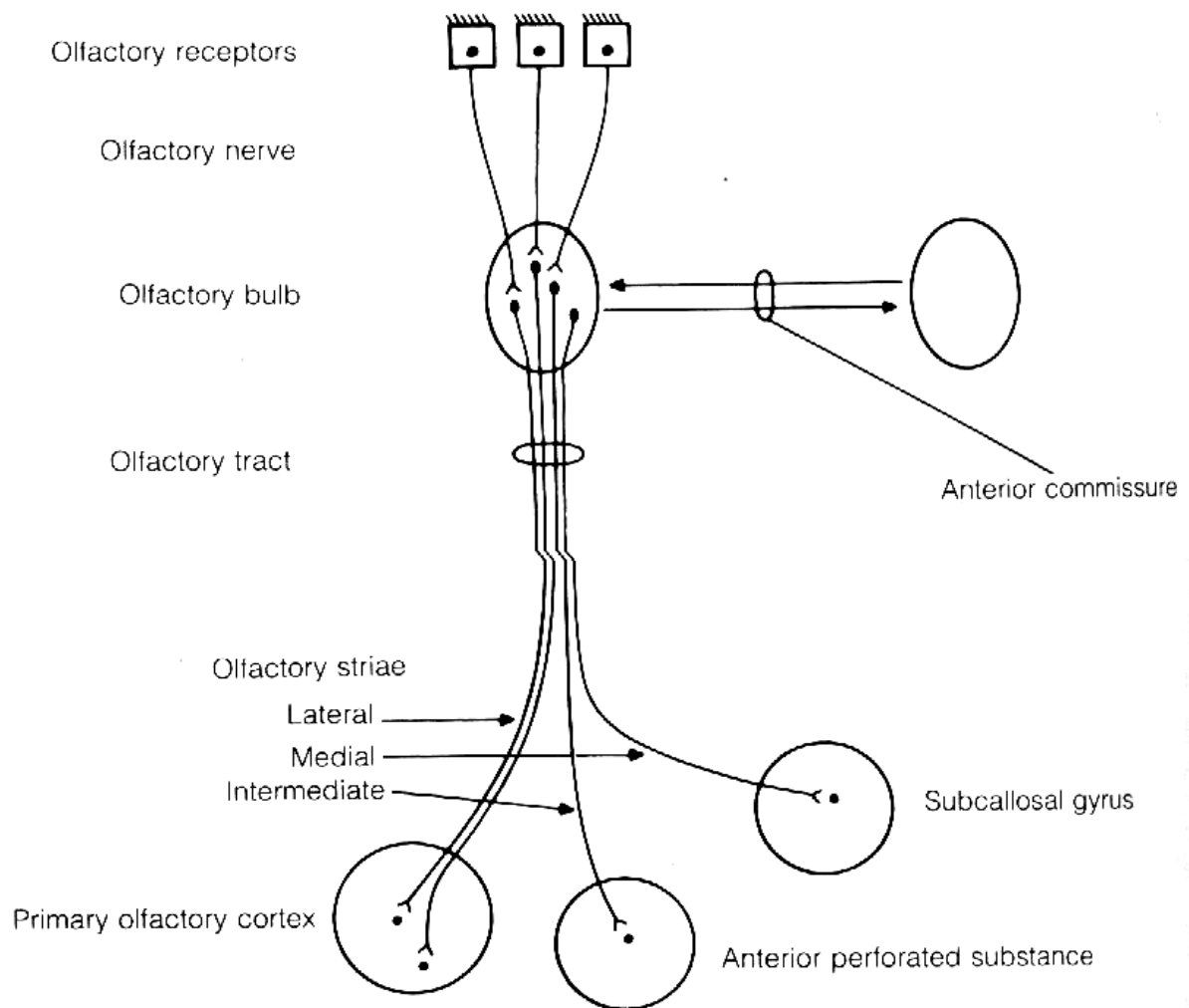


Figure 1. Schematic diagram of the olfactory pathways

Results of examination

1- Normal results. This include: those who recognize and name odors quickly (usually women), those who recognize but they cannot name the odors (usually men), and those who can detect a smell and easily distinguish differences, but can neither recognize nor name odors.

2-Parosmia. Those for whom, each odor smells the same but is distorted and unpleasant.

3-Anosmia. Those who can smell nothing in one or both nostrils, or those whose sense of smell is much reduced on one side compared with the other, but careful examination of the nasal passages is necessary to distinguish neural from local disease.

Localization of lesions affecting the olfactory nerve

Lesions causing anosmia

- 1- Local nasal disease: e.g. allergic rhinitis, heavy smoking. These are usually bilateral and a local examination solves the problem.
- 2- A neural lesion: After a local nasal disease had been ruled out, anosmia, especially unilateral anosmia, should raise the suspicion that a lesion may affect the olfactory nerve, filaments, bulb, tract, or stria and because the cortical representation for smell in the piriform cortex is bilateral, a unilateral lesion distal to the decussation of the olfactory fibers causes no olfactory impairment. Sites of damage to the olfactory pathway and their common causes are as follow:
 - a. Olfactory filaments: Head injury is probably the commonest cause of disruption of the olfactory fibers prior to their decussation. The olfactory nerve proper (olfactory filaments) may be torn by fractures involving the cribriform plate of the ethmoid bone, but closed head injury without fracture may also disrupt the olfactory pathways unilaterally or bilaterally.
 - b. The olfactory bulb and tract: These are frequently affected by tumors of the olfactory groove (especially meningiomas), which may cause the Foster-Kennedy syndrome. Other causes include tumors of the sphenoid or the frontal bones e.g. osteomas, pituitary tumors with suprasellar extension, aneurysms of circle of Willis, diffuse meningeal process e.g. meningitis, and mass lesions of the frontal lobe e.g. glioma or abscess. Damage to the olfactory system may be bilateral (trauma and infection) or unilateral (e.g. frontal lobe tumors). Table (6) illustrates the important sites of damage to the olfactory pathway.

Lesions causing parosmia

This phenomenon is usually seen after head injury or with psychiatric diseases like depression.

Table 6. The sites of damage to the olfactory pathway.

Site	Example
Nasal mucosa	Upper respiratory tract infection
Cribriform plate	Head trauma
Olfactory bulb and tract	Frontal meningioma
Temporal lobe	Trauma or tumor

2-2 The Second Cranial Nerve (The optic nerve)

Functions

- 1- It carries visual impulses from the retina to the lateral geniculate body.
- 2- It acts as the afferent pathway for the pupillary light reflex.

Purposes of the tests

- 1- To measure the visual acuity (VA) and to decide if any defect is due to local ocular disease or in the visual pathway.
- 2- To examine the visual fields (VF).
- 3- To examine the fundus.

Visual acuity

Methods of testing

1-Test for distant vision: VA is measured with Snellen's test types^{*}. The patient reads down the chart as far as he can. If only the top letter of the chart is visible, the VA is 6/60. A normal person should read at least the seventh line i.e. VA of 6/6. If the VA is less than 6/60, the patient is moved toward the test chart until he can read the top letter. If the top letter is visible at 2 meters, VA will be 2/60. VA of less than 1/60 is considered as counting fingers (CF), hand movement (HM), perception of light (PL), or no perception of light (NoPL).

* The patient is normally placed at 6 meters from the chart and each eye is tested separately.

- 2- Test for near vision: Jaegar type cards are used for testing, it must be held one foot from the patient's eye. Average acuity lies between Jaegar 1 and Jaegar 4. Rough examination can be made by asking the patient to read a newspaper.

Loss of visual acuity (localization)

- 1- Ocular disorders: They represent the commonest causes of visual failure, they are too numerous to list, but include all refractive errors, cataract and vitreous opacities.
- 2- Retina: VA is normal, if macula is spared, decreased if macula is affected.
- 3- Optic nerve: Virtually all compressive and most of the non-compressive lesions of the optic nerve cause drop in VA, often before a visual field defect can be detected.
- 4- Optic chiasm: VA is decreased in both eyes when the medial part of the chiasm is affected. Decreased in the eye ipsilateral to a lateral chiasmatic lesion.
- 5- Retrochiasmatic lesion: Unilateral lesions of the optic tract, lateral geniculate body, visual radiation or the occipital cortex do not impair VA. When the lesion is bilateral VA falls to the same degree in both eyes.

Visual fields (VF)

The shape and distribution of VF loss reflect the site of the lesion exactly, so good examination of the VF is most helpful in localization of lesions of the visual pathways when we examine a cooperative patient.

Purposes of the tests

- 1- To chart the periphery of the VF and their extent. This is about 160 degrees in the horizontal plane and about 135 degrees in the vertical plane when we examine one eye.
- 2- To detect the position, size, and shape of the blind spot.
- 3- To detect any abnormal scotomas.

Methods of examination

Numerous methods exist for measuring the VF which like the VA must be examined separately for each eye. The followings are the most practical and valuable methods:

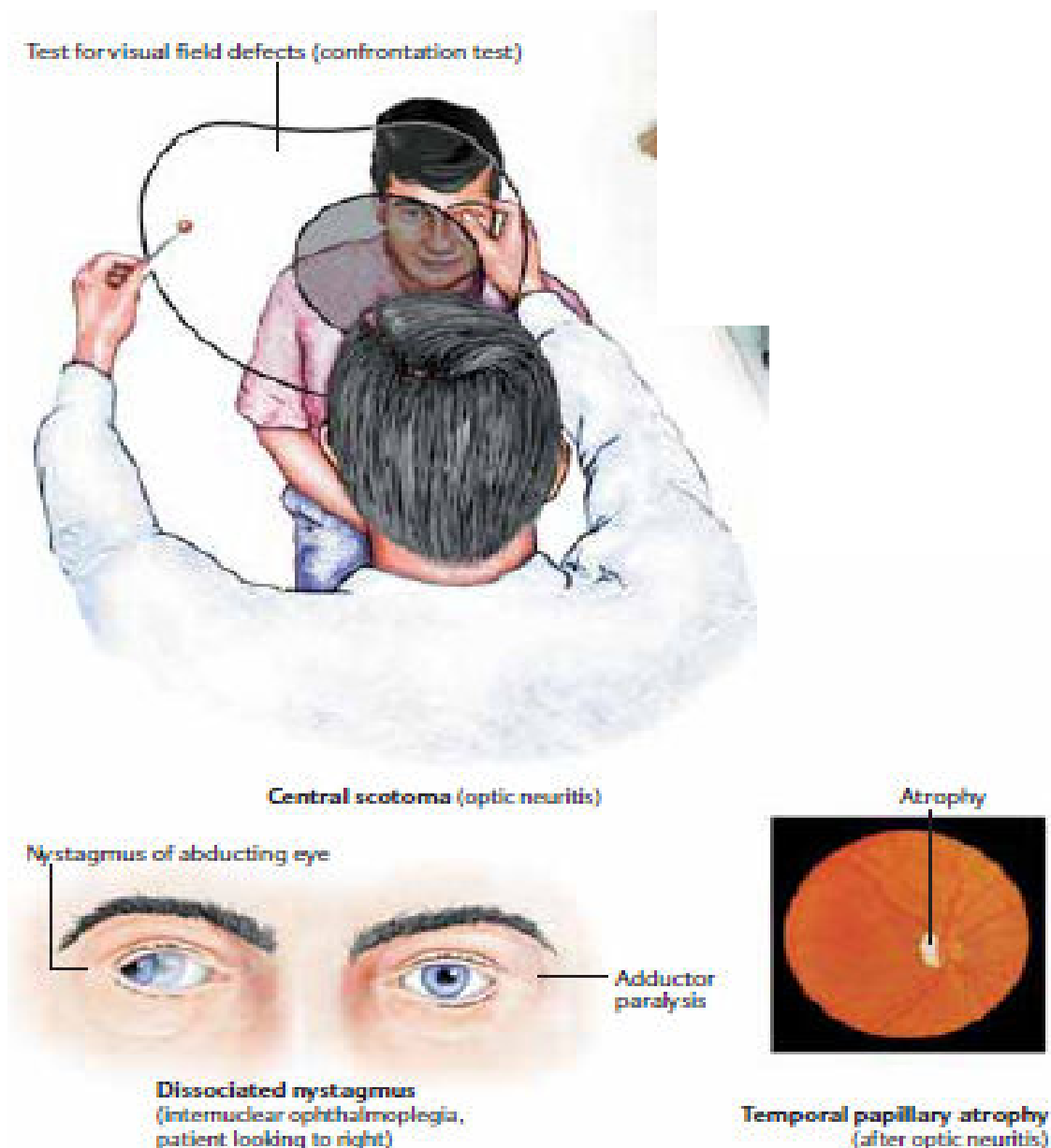
A- Confrontation

Do not underestimate the value of testing by confrontation. A surprising degree of accuracy is possible with a cooperative patient. The following parameters can be tested by confrontation.

- 1- The peripheral fields: The patient and the examiner face each other at a distance of about one meter from each. The examiner close (say) the right eye and the patient cover the left eye. Ask the patient to fix carefully on the examiner's pupil while the examiner move test objects of varying size (the whole hand, moving finger, a white head pin) inward in each of the four quadrants from just outside the limits of his own fields, at first from almost a full arm length to the side midway between the patient face and your own. The patient must say the moment he sees the object and whether it is of equal clarity in each quadrant, for graying of vision often precedes a measurable defect. If he fails to see the moving object (fingers), keep bringing the hand nearer until he does see them. The boundaries are then defined by determining the farthest peripheral sites at which the patient can detect slight movement of the fingertips.
- 2- The blind spot: The patient's blind spot can be located in the region of the examiner's own blind spot, and the size of these spots can be compared using a red head pin. The procedure is then repeated for the other eye. It should always possible to identify this blind spot when testing the VF to confrontation, and its size should be correspond with the examiner's own blind spot when the red pin is held equidistant between the examiner's eye and the patient's eye. The physiological blind spot is situated to the temporal side of central point of fixation of the VF. It represents the optic disc which is devoid of receptor cells. The blind spot sometimes appears

to be absent in an uncooperative patient, or if the patient is attempting to mislead the examiner.

- 3- The central fields: The central area of vision can be tested in order to map out any scotoms by using a red head pin and by confrontation. The examiner moves the target from the central area of the field outwards in every direction upward, downward, to the right and to the left, or he may move the red head pin from outside inward in a cross manner. Central scotomas can be recognized by this method either because the red head can not be perceived in the scotoma, or in less severe examples, because the intensity of the red color is reduced in this part of the field.



B-Perimetry

In cooperative patient, central VF testing with the tangent (B Jerrum) screen and peripheral testing with a modern perimeter, using a stimuli of different colors provide a detailed map of the VF.

Interpretation of the results: Peripheral fields defects (Figure 2).

- 1- Total unilateral loss of vision: This is caused by a lesion of the ipsilateral optic nerve. It is commonly caused by retrobulbar neuritis, and optic nerve compression.
- 2- Bitemporal hemianopia: This is caused by lesions at the optic chiasm. It is commonly caused by pituitary tumors, craniopharyngioma, suprasellar meningioma, midline aneurysms, hypothalamic neoplasm, gross 3rd ventricle dilatation and optic chiasmal glioma.
- 3- Bitemporal upper quadrantic defect: This is caused by early stages of chiasmal compression from below. It is caused commonly by pituitary tumors.
- 4- Bitemporal lower quadrantic defect: This is caused by early stages of chiasmal compression from above. It is commonly caused by intrinsic tumors of the hypothalamus, suprasellar cysts or meningioma. This defect is not a very common defect.
- 5- Homonymous hemianopia: This is the commonest major defect, caused by a lesion anywhere from the optic tract to the occipital cortex. In the tract it is usually complete, incongruous and without macular sparing. In the radiations, it is usually incomplete, congruous with macular sparing. In the calcarine cortex, it is usually complete, congruous, and with macular sparing, but may show associated scotomas, congruity and macular sparing are variable. It is caused commonly by vascular disorders, cerebral tumors, vascular anomalies and injuries.
- 6- Upper quadrantic homonymous defect: It can be caused by temporal lobe lesions involving the optic radiation, where they sweep round the temporal horn of the lateral ventricle, less commonly in the lower

calcarine lesions, occasionally in partial tract lesions. It is caused commonly by cerebral tumors, vascular diseases, cerebral abscesses, and injuries.

- 7- Lower quadrantic homonymous defect: This could be caused by lesions of the upper radiations in the parietal lobe or the calcarine area. It is caused commonly by vascular diseases, injuries and tumors.
- 8- Binasal hemianopia: It is very rare but can be caused by bilateral lesions confined to the uncrossed optic fibers on each side of the optic chiasm, and it may also occur in open angle glaucoma.
- 9- Concentric constriction: Sometimes occur in long standing papilloedema, in bilateral lesions of the striate (visual) cortex and in some retinal disorders like retinitis pigmentosa. It is also found in hysteria.

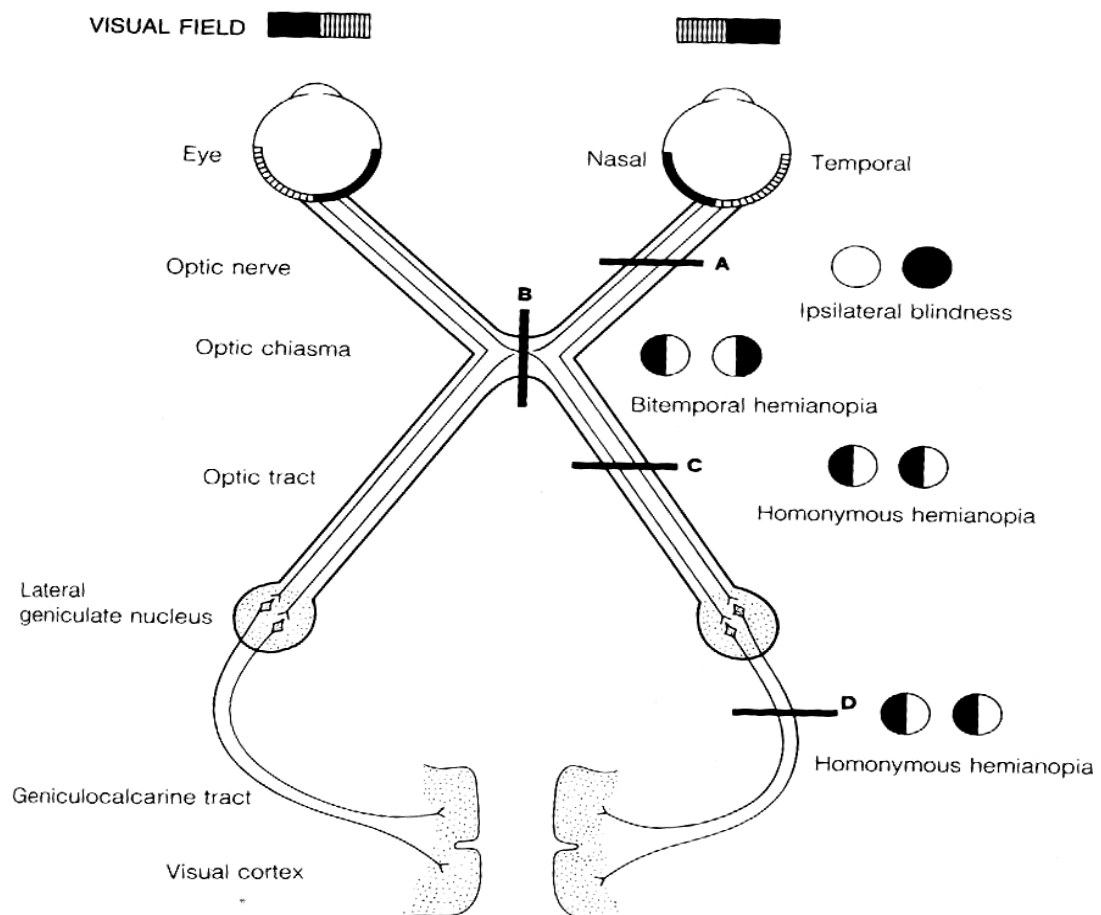


Figure 2. Schematic diagram of the visual pathway showing clinical manifestations of lesions in various sites

A- Central field defects

The most important factor in localizing the lesion is to note whether the field defect is monocular, in which case the lesion usually affect the retina or the optic nerve; or binocular, in which case the lesion is localized to or beyond the optic chiasm. Obviously, multiple lesions in the visual pathway, which occur frequently with multiple sclerosis and other conditions, may result in bilateral loss even when the anterior optic pathways are involved.

I-monocular scotomas

- 1-** Central and centrocaecal scotomas: Intrinsic lesions of the optic nerve between the chiasm and the optic nerve head, central scotoma indicate macular involvement, centrocaecal scotoma indicate involvement of the macula and the papillomacular bundle. Causes include multiple sclerosis and optic nerve gliomas.
- 2-** Arcute scotoma: It indicates involvement of the retina or the optic nerve back to the chiasm. They are located in the nasal field. In retinal disease the tip of the scotoma not reach the blind spot while in optic nerve lesions it reaches the blind spot. They take this shape because of the arrangement of the retinal fibers in the temporal part which like an arc. Causes include: vascular lesions, toxins, optic nerve gliomas, demyelinating lesions.
- 3-** Sector shape scotoma: Defect in the temporal field lateral to the blind spot have an appearance of sector rather than an arc, the straight course of the nasal retinal fibers toward the optic nerve head explain this shape. They also occur in retinal and optic nerve lesions due to the same causes.
- 4-** Crescent shape scotoma: Peripheral field defect due to involvement of retina or optic nerve back to the chiasm, but also could occur in lesions located in the most anterior extent of the calcarine cortex. Common causes include vascular and demyelinating lesions.
- 5-** Junctional scotoma: A central defect in one field with superior temporal defect in the opposite field. It points to lesions in the anterior angle of the

chiasm, which damage the ipsilateral optic nerve and the loop made by fibers from the inferonasal retina of the other eye called the Wilbrand's knee.

- 6- Monocular altitudinal defect: It is characteristic for diseases in the distribution of the central retinal artery and usually accompanied by macular sparing because it gets its blood supply from the cilioretinal arteries.
- 7- Enlarged blind spot: Commonly caused by papilledema from increased intracranial pressure.

II-Binocular scotomas

- 1- Bilateral altitudinal defect: It may result from bilateral ischemic disease of the retinas or optic nerves, but bilateral occipital lesions are more commonly responsible for this type of defect.
- 2- Bilateral ring scotomas: It may be the consequence of retinal disease, like retinitis pigmentosa. These ring defects have characteristic horizontal step between the 2 halves of the ring. Bilateral occipital lesions may cause a similar defect. However in occipital lesions, vertical step can regularly be identified between the 2 halves of the ring.
- 3- Bitemporal scotomas: In chiasmal lesions, the peripheral field may be affected later. Commonly caused by the same causes of bitemporal hemianopia, but with special reference to glioma of the optic chiasm if in children.
- 4- Homonymous scotoma: unilateral lesion of the tip of the calcarine cortex. Commonly caused by injuries or tumors.

Fundoscopy

The fundus must always being examined in all patients whether they have neurological or medical complaints. Skills in detecting early abnormalities come only from inspecting a large number of fundi. Finding unexpected abnormalities may alter the whole problem.

Methods of examination

- 1-** Instruct the patient to look at a distant point which had been clearly defined for him, thus overcoming the accommodation reflex.
- 2-** Diminish if necessary the illumination of the room in order to overcome the light reflex.
- 3-** Use the right eye and the right hand to examine the right eye of the patient and then walk around the bed to examine the left eye of the patient with your left eye holding the ophthalmoscope with your left hand. Leaning over the patient is uncomfortable and prevents him from fixing on a distant object, while using the wrong eye result in nasal collision.
- 4-** The ophthalmoscope should then be brought as close as possible to the patient eye and the light slightly directed nasally. In this way the optic disc can be found and, in addition, the light will not shine directly on the macula. If the patient's pupils are not dilated shining a light on the macula will lead to miosis and may make the examination of the fundus difficult or impossible.
- 5-** If the optic disc is not in focus, the strength of the lenses of the ophthalmoscope should be gradually adjusted until the disc is sharply focused. The optic disc, the retinal blood vessels, the retina itself including the macular region and the periphery of the fundus should be examined in turn.

Features to be examined

For purpose of easy memorization these include **6 Cs**

- 1- Color:** The normal disc has a pale- pink color, distinctly paler than the surrounding fundus. The temporal side of the disc is usually paler than the nasal side. In atrophy of the optic nerve the disc becomes pale and may even become white or grey-white in color. I edema the optic nerve head, the disc is pinker than normal and may approach the color of the surrounding retina. In psedopapilloedema, a congenital anomaly sometimes associated with hypermetropia, the disc may appear swollen and pinker than normal, but the

retinal blood vessels are normal in appearance, corrected vision is normal and the condition is stationary

- 2- Contour (edge of the disc):** This is normally well defined a part from the nasal edge which is normally somewhat blurred. In normal eyes there is sometimes a white scleral ring, a dark-pigmented ring, or a stippled choroidal ring surrounding the optic disc.
- 3- Cup (physiological cup):** It is depression in the center of the disc which is paler than the surrounding disc, and from it the retinal vessels enter and leave the eye. In glaucoma, the cup may be greatly increased in size and the retinal vessels will kink as they cross the edge of the disc, this may give a wrong impression of optic atrophy. However in this condition there is usually a rim of normal disc. In addition there is always increased intraocular pressure which must be always be checked if you face this problem.
- 4- Circumference:** The normal disc is round or slightly oval. If astigmatism is present, the disc may appear more oval than normal.
- 5- Circulation (the retinal vessels):** These radiate from the disc dividing into many branches as they pass toward the periphery of the retina. The following points must be noted when you examine the retinal vessels.
 - a.** The character of the vessels: The arteries are narrower and lighter than veins and often have a central reflecting line, so that a "silver wire" appearance can be quite normal.
 - b.** Continuity of the vessels: See if the vessels are continuously visible or if they appear and disappear as they reach the disc as in cases of papilledema and glaucoma.
 - c.** The curvature of the vessels: Note if the curves of the vessels are gradual (normal) or acute and tortuous (Abnormal).
 - d.** Crossing point: It is important to study the points where arteries and veins cross. More frequently it is the artery that crosses the vein, and

in normal conditions neither the artery nor the vein show any change in color, diameter and direction.

- e. Spontaneous venous pulsation: It is frequently seen in normal fundus, it never occurs in papilledema. If it is absent, it doesn't necessarily indicate increased intracranial pressure.

6- Curiosities (chorioretinal): Lastly we inspect the retina systematically, inspecting each quadrant in a clock wise pattern. Each abnormality must be described in details. Its position described in term of clock's numbers. The distance of the abnormality from the optic disc in term of disc diameter from the border of the optic disc. For example, we say that dot or blot hemorrhage is noticed at 9 o'clock about 2 disc diameter from the optic disc border.

After we complete the examination of the retina and while the patient is fixing at a distant object, now we ask him to look directly at the light, when the vessels free **macula** can be seen. This area is situated 2 disc diameter from the optic disc border. It is recognized by being darker in color than the surrounding fundus.

The following are the most important for neurologists:

Abnormalities of the fundus

1- Abnormalities of the optic disc:

- a. Optic atrophy.
- b. Optic nerve swelling.
- c. Opaque or medullated nerve fibers.
- d. Myopic crescent.

2- Retinal vessels abnormalities:

- a. Retinal arteriosclerosis.
- b. Hypertensive retinopathy.
- c. Occlusion of the central retinal artery.
- d. Occlusion of the central retinal vein.

3- Retinal abnormalities:

- a. Retinal hemorrhages.

- b. Retinal exudates.
- c. Retinal tubercles.
- d. Retinal phakomata.
- e. Pigmentary abnormalities.

Optic atrophy

In this condition the optic disc appear paler than normal and may even be white. Because of the wide variation in color of the optic disc, a useful sign of optic atrophy is the decrease in the number of capillaries on the disc. In optic atrophy, the number of capillaries that cross the disc margin is reduced from the normal of (10-5) (Kestenbaum's sign). There are three main varieties of marked optic atrophy:

- 1- Primary optic atrophy: The disc is flat and quite white with clear cut edges. It is due to local lesions of the optic nerve such as, ischemic neuropathy, pressure on the nerve, optic neuritis, injuries, toxins e.g. tobacco, alcohol, lead, ...etc; tabes dorsalis and certain familial disorders e.g. leber's disease.
- 2- Secondary (consecutive) optic atrophy: The disc is grayish-white in color and its margins are indistinct (blurred). It follows swelling of the optic disc due to papilledema.
- 3- Temporal pallor: The disc is apparently pale in quadrantic or crescentic manner on the temporal half due to lesion principally of the papillomacular bundle. This is often seen in cases of multiple sclerosis, but it is neither constant in that disease, nor pathognomonic of it.

Differential diagnosis of optic atrophy

- 1- Myopic disc: Normally looks very pale and appears greatly enlarged. Examine it through the patient's own spectacles will help you to get the best view. If the patient is not known to be myopic, adjustment of the ophthalmoscope lenses to get the best focus of the disc will solve the problem.
- 2- Enlarged physiological cup.

Optic nerve swellings

This is of two types:

A- Papilledema: This is swelling of the optic nerve head due to increased intracranial pressure. Fundoscopic appearance varies according to the stage of the papilledema. The followings are the different stages of evolution of papilledema:

- 1- Engorgement of the retinal vessels.
- 2- Blurring of the disc margins.
- 3- A redder disc with loss of the physiological cupping of the disc.
- 4- Advanced stage: In addition to the above findings, there are a lot of retinal hemorrhages and exudates.

B- Papillitis: This is due to local disease that affects the optic nerve head. There is hyperemia and some swelling of the optic disc. It must not be confused with papilledema in spite of their ophthalmoscopic appearances.

(Table 7) list the important differences between the 2 conditions

Table 7. Clinical differences between papilledema and papillitis

Papilledema		Papillitis	
1-	Usually bilateral	1-	Usually unilateral
2-	VA is normal	2-	VA is markedly reduced.
3-	VF shows enlargement of the blind spot	3-	VF discloses central or centrocaecal scotomas.
4-	The swelling of the optic disc is usually severe with marked engorgement of the vessels.	4-	The swelling of the optic disc is usually slight, retinal veins engorgement is less marked.
5-	No signs of inflammation.	5-	There may be signs of inflammation
6-	There are usually exudates and hemorrhages in the advanced stages of papilledema.	6-	There are usually no exudates or hemorrhages. Although, it can occur in adolescent with very acute optic neuritis.

Opaque or medullated nerve fibers

These usually present as one or more white patches radiating from the optic disc for a short distance. The patch has a characteristic feathered edge and retinal vessels may disappear for a short distance within it. This condition is a harmless and non-progressive congenital anomaly

A myopic crescent

This is a ring of exposed white sclera, usually on the temporal side of the optic disc, but sometimes extending all round it. When marked, it may be associated with other degenerative changes in the fundus, which if they involve the macula, will result in reduction of central vision.

Retinal arteriosclerosis

This occurs as either exaggeration of the general aging process, or in association with hypertension. It is characterized by:

- 1- Broadening of the arterial light reflex, producing a "copper wire" or "silver wire" appearance.
- 2- Tortuosity of the vessels.
- 3- Nipping, indentation or deflection of the veins, where they are crossed by the arteries.
- 4- White plaques on the arteries.
- 5- In hypertension, "flame shaped" hemorrhages and "cotton wool" exudates in region of the macula.

Hypertensive retinopathy

The following grades may be seen in hypertensive fundus according to the severity:

Grade I: Irregularity of the lumen of the arterioles with increased light reflex.

Grade II: Shows arterio-venous nipping.

Grade III: Shows hemorrhages, most commonly flame shaped and exudates.

Grade IV: Shows papilledema.

Occlusion of the central retinal artery

- 1- The optic disc and surrounding retina are pale (optic atrophy).

- 2- Cherry red spot at the macula.
- 3- The arteries are narrow or even thread like and there are many streaky hemorrhages around the vessels.
- 4- The veins are also narrow with less blood than normal.
- 5- VA—total blindness.

Common causes: cranial arteritis, emboli from infective endocarditis, disseminated atherosclerosis.

Occlusion of the central retinal vein

- 1- Papilledema which is usually unilateral.
- 2- Gross venous engorgement and numerous hemorrhages (sausage like veins).
- 3- VA is markedly affected.

Common causes: hyper viscosity syndromes (multiple myeloma, myeloproliferative disorders), hypertension, diabetes mellitus.

Retinal hemorrhages

These occur in a number of different conditions and are due to one or more of the following factors:

- 1- Increased blood pressure in the retinal vessels as in hypertension.
- 2- Abnormalities in the walls of the retinal vessels, as in arteriosclerosis, diabetes mellitus, and occlusion of the retinal vein.
- 3- Abnormalities in the circulating blood, as in anemia, leukemia, and bleeding diathesis.
- 4- Sudden reduction in the intraocular pressure, following operating wound (surgical or traumatic) of the eye.

Shape of the hemorrhage varies according to its relation to the retina, etiology, and duration. The following types of hemorrhages are commonly encountered:

- 1- Small streaks, near the vessels, long and linear, or flame shaped. These are usually superficial, commonly seen in hypertension, increased

intracranial pressure, venous engorgement of any cause e.g. collagenosis and blood dyscrasias.

- 2- Large blots and spots or dots: These usually lie deep in the retina, caused by the same causes of small streaks hemorrhages.
- 3- Micro-aneurysms: These are small rounded pin-heads areas of the retinal vessels, occur in diabetes.
- 4- Subhyaloid hemorrhages: These are seen in cases of subarachnoid hemorrhage. They appear as large round hemorrhages related to and often below the disc, with a straight, horizontal upper border like boat.

Retinal exudates

The appearance of exudates is not diagnostic and must be correlated with the appearance of the disc and vessels. Exudates are generally of two types:

- 1- Soft exudates (cotton wool): These are poorly demarcated superficial ischemic areas of the retina, or localized collection of edema fluid in the nerve fiber layer which indicate the onset of the accelerated phase of hypertension, and commonly disappear within a few weeks with good control of hypertension.
- 2- Hard exudates: These are small, deep, dense, deposits of lipids and have well defined borders. They persist much longer than the soft exudates.

The important causes of exudates are:

- 1- Hypertension.
- 2- Diabetes mellitus.
- 3- Systemic lupus erythematosus (cytoid bodies).
- 4- Severe anemia.
- 5- Leukemia.
- 6- Chorioiditis.
- 7- Retinitis pigmentosa.

Retinal tubercle

Choroidal tubercle appears, under ophthalmoscopic examination, much longer than tubercles as seen as post-mortem. They are rounded, about half the size of the disc, yellowish at the center, but with ill-defined pink edges, slightly raised and, if present, for any length of time, surrounded by pigmentation.

Retinal phakomata

A phakoma is collection of neurological cells appearing in the retina as a large white, or bluish-white, plaque with almost translucent edges, about one half to two third the size of the disc. Though on occasion seen in neurofibromatosis, they are most characteristically a feature of tuberous sclerosis.

Pigmentary abnormalities

Many choroido-retinal pigmentary lesions are not directly of neurological problem. The following conditions are of importance to the neurologist.

- 1- Cherry-red spot: This may be seen in cerebro-macular degeneration.
- 2- Choroiditis: These appear as white-opaque exudates of variable size surrounded by black pigmented margin. The retinal vessels are always superficial to the exudates. Common causes of choroiditis include: toxoplasmosis, sarcoidosis, tuberculosis, syphilis and trauma. Any of the above diseases may involve the nervous system.
- 3- Retinitis pigmentosa: The exudates are the same as in choroiditis, but the essential difference is that the exudates in retinitis pigmentosa interrupt the vessels since the exudates are much more superficial. The optic disc is usually atrophied and the patient has tunnel vision. The neurological importance of this condition is that it may give an impression about the diagnosis of certain neurological disorders that may be associated with this condition, like Refsum disease, in which condition the patient will have in addition ataxia and peripheral neuropathy. Much more commonly, the patient has Laurence-Moon-Biedle syndrome.

3-3 The third, the fourth, & the sixth cranial nerves

(The oculomotor, the trochlear, & the abducent nerves)

Functions

- 1- They control the external ocular muscles and the elevators of the lids.
- 2- They regulate the pupillary size by the parasympathetic fibers that run with the oculomotor nerve (Figure 3).

Purposes of the tests:

Examination of the ocular nerve is aimed to look for and analyze the following ocular signs:

- 1- Ptosis.
- 2- Proptosis.
- 3- Pupils (anisocoria)
- 4- Squint.
- 5- Diplopia.
- 6- Nystagmus.

Methods of examination

- 1- Inspection: Look for ptosis, proptosis, and pupils (anisocoria). This is best noted by asking the patient to look constantly at clear and definite point such as the point of a pen holds at neutral (primary position) of the eyes at about 50 cm in front of them.
- 2- Ocular movements: From the neutral position, the examiner then move the point of the pen and ask the patient to follow this movement like the letter (H), i.e. to the left up and down then to the right up and down. Do not attempt to move the eyes beyond the point of comfort and hold each deviation for about 5 seconds. During eye movement look for squint (eye lag), diplopia, and nystagmus.

Interpretation of the results

Ptosis

It means drooping of the eyelids reaching the pupil and covering part of it. Normally the upper lid covers 1-2 mm of the iris.

- ❖ Determine whether the ptosis is unilateral or bilateral, partial or complete, with or without over contraction of the frontalis muscles.
- ❖ Examine the size and the shape of the pupils, look for squint, and test light and accommodation reflexes to differentiate between third nerve palsy and Horner's syndrome.
- ❖ Look for any evidence of myopathy and other features of dystrophia myotonica e.g. cataract, gonadal atrophy, and frontal baldness.

Causes of ptosis

- 1-Third nerve palsy. Ptosis is usually complete, unilateral (if peripheral lesion), bilateral (if nuclear lesion) and with overcontraction of the frontalis muscle. Other features of third nerve palsy are usually present which include: double vision, divergent squint with or without dilated pupil.
- 2-Sympathetic paralysis (Horner's syndrome). The ptosis is always partial with small pupil, the eye is small and sunken (enophthalmos), the lid can still be raised voluntarily. It is usually unilateral. Bilateral spontaneous sympathetic palsy almost invariably means an upper brainstem lesion.
- 3-Tabes dorsalis. Ptosis is usually bilateral with overcontraction of the frontalis. Some degree of ophthalmoplegia is also present. Look for other features of tabes dorsalis elsewhere in the body like ataxia, loss of reflexes, etc.
- 4-Myopathies. Like facioscapulohumeral myopathy, dystrophia myotonica, ocular pharyngeal dystrophy, mitochondrial myopathy like progressive external ophthalmoplegia (PEO) and Kearns sayrs syndrome. Ptosis is usually progressive, no overcontraction of frontalis and the typical other features of myopathies
- 5-Myasthenia gravis. The degree of ptosis varies from moment to moment and may change the sides. The lid will droop progressively on prolonged upward

fixation, but a blink will restore its position to normal. No overcontraction of frontalis.

6-Congenital. It is a common cause of bilateral or unilateral partial ptosis, with overcontraction of frontalis.

7-Hysterical ptosis. Very rare and is always unilateral.

Proptosis

It is forward displacement of the eye balls. It is best detected by examination of the patient in profile or from above. The following points must be checked in every patient with exophthalmoses:

- 1-Note the lid retraction, with wide palpebral fissure.
- 2-Test for the presence of lid lag.
- 3-Check the movement of the eye balls to rule out (exophthalmic ophthalmoplegia).
- 4-Listen to any bruit over the eye balls.
- 5-Examine the neck for any thyroid enlargement
- 6-Check for tremor, tachycardia, atrial fibrillation and pretibial myxoedema

Causes of unilateral proptosis

- 1-Thyrotoxicosis.
- 1- Orbital or retro-orbital neoplasm or infections.
- 2- Pseudo-tumor (orbital pseudo-tumor): This is an inflammatory or granulomatous reaction which involves the cavernous sinus, orbital and retro-orbital parts. They cause painful ophthalmoplegia due to involvement of the third, fourth, sixth, first and second divisions of the fifth cranial nerves. They are benign, recurrent, and usually show dramatic response to steroids. They are best diagnosed by ultrasound or CT scan of the orbit and must be differentiated from the same reactions which occur in the superior orbital fissure and anterior part of the cavernous sinus (Tolosa-hunt syndrome). In the latter condition there is no proptosis, or injection of the conjunctiva.

- 3- Carotid artery-cavernous sinus fistula: The globe is pulsatile and there is audible bruit (audible for both the patient and the examiner).
- 4- Cavernous sinus thrombosis: Usually seen with marked chemosis and ophthalmoplegia.

Causes of bilateral proptosis

- 1- Grave's disease (thyrotoxicosis).
- 2- Craniostenosis
- 3- Hydrocephalus.
- 4- Cushing's disease (steroid myopathy).
- 5- Chronic increase in the intracranial pressure.
- 6- Cavernous sinus thrombosis and all causes of the unilateral proptosis may involve the other side.

Pupils

Methods of examination

- 1- Inspection: Look at the size, shape, equality, and regularity of the pupils. Correlate the size of the pupils with the degree of light in the room. It is normal for the pupils to be small in early infancy, old age, during sleep and in bright light. Normal large pupils may be seen in myopia, dark room and frighten children.
- 2- The reaction to light: A light is shown suddenly from one side of the eye after asking the patient to look into distance e.g. across the room to be sure that his accommodation is relax. The pupil should constrict briskly. Repeat the test for the other eye and compare the two reactions. Finally shield one eye and shine the light in the other eye and watch for the consensual light reflex which is the constriction of pupil in the shielded eye.
- 3- The reaction to accommodation: The pupillary reaction to accommodation composed of bilateral ptosis, convergence, and miosis. Hold up one finger close to the patient's nose. Ask him to look away at a distant object. Then ask him to look quickly at your finger and note the pupillary responses. Accommodation is only rarely lost in brain stem lesion, but may be impaired

in lesions of the third cranial nerve and certain neuropathies in which there is autonomic impairment. Figure 3 demonstrate the anatomy of light reflex.

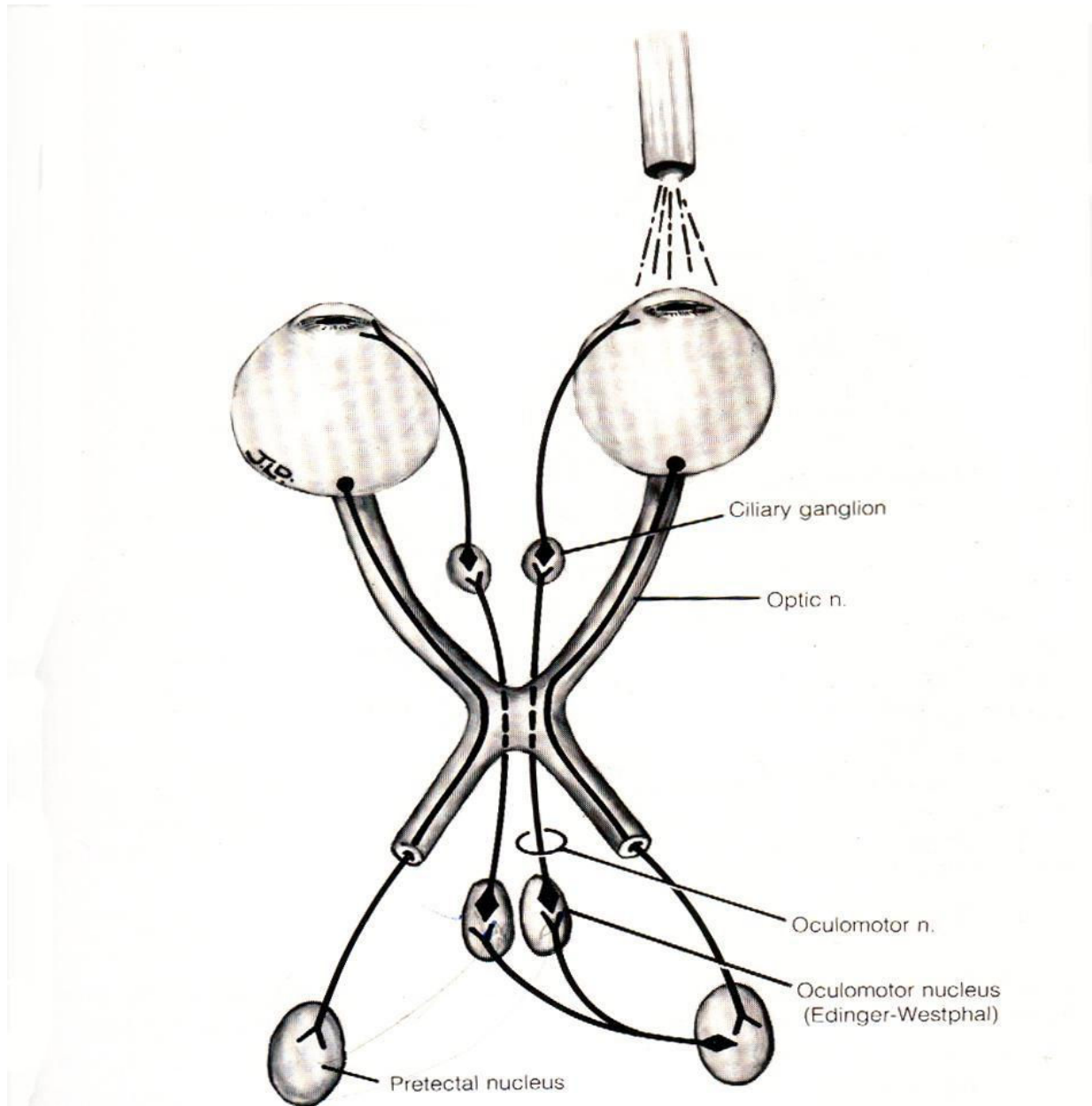


Figure 3: Schematic diagram showing the afferent and efferent pathways of the light reflex

Pupillary abnormalities

1- Miosis

An abnormally small pupil (miosis) is a sign of lesion in the sympathetic pathway which supplies the pupillary dilator muscle. Classically oculo-sympathetic paralysis results in a Horner syndrome which comprises the triad of miosis, ptosis, and anhidrosis of the forehead. Diameter is usually reduced by 0.5-1.0 mm compared with the normal side.

This inequality is most marked in dim illumination. Other features of Horner syndrome include the presence of dilatation lag; no response to cocaine test (2%-8%) and Hydroxyamphetamine usually cause dilatation if the lesion is preganglionic. Pattern of anhidrosis can help in the localization of the lesion. If sweating is decreased on the entire half of the body and the face, the lesion is central. Cervical lesions produce anhidrosis of the face neck and arm. Sweating is unimpaired in post-ganglionic lesions.

Causes of Horner's syndrome:

- 1- Lesions of the brainstem.
- 2- C8-T1 lesions e.g. syringomyelia.
- 3- Lesions in the neck e.g. Trauma, lymphadenopathy, cervical ribs.
- 4- Lesions in the superior mediastinum e.g. aneurysm, glandular enlargement, bronchial carcinoma.

2- Mydriasis (dilated pupil)

A variety of lesions, some of them purely ocular, such as uveitis, may give rise to a fixed dilated pupil. Neurologically, there are three main diagnostic considerations:

I- Surgical Third nerve palsy. This is due to interruption in the parasympathetic fibers. It is a safe clinical rule that the interruption of these fibers is particularly always associated with ptosis, impairment of the extra ocular movements, or signs of other brain stem or cerebral disease. Sphincter is not supersensitive to 0.1% pilocarpine but constrict when we apply 1% pilocarpine. Commonest causes are: aneurysms, tumors, or temporal lobe herniations.

II- Adie's tonic pupil. This is a unilateral (rarely bilateral) dilated pupil of no sinister significance. The pupil reacts slowly and only to persistent bright light or 0.25% pilocarpine eye drops. Accommodation is less affected. Absent deep reflexes in the limbs is a common accompanying feature, especially the knee, and ankle jerks. Site of pathology is uncertain.

III- Drug induced mydriasis. A mydriatic fixed pupil is the result of accidental or deliberate application of an atropinic or sympathomimetic drug. Failure of 1%

pilocarpine drops to contract the pupil provides proof that the iris sphincter has been blocked by atropine or some other anticholinergic agents.

3-Non-reactive pupils. This is due to a break in the pathways for the light reflex. The lesion may lie in the afferent loop i.e. the retina, optic nerve, and optic chiasm; or in the efferent loop i.e. the parasympathetic supply from the midbrain running with oculomotor nerve. If the afferent loop is involved, both the direct and consensual reaction will be lost, if the diseased side is stimulated. If the normal side is stimulated, both pupils will react. If the efferent loop is involved, the affected pupil can not react, no matter which side is stimulated. Bilateral failure to react plus intact vision usually means a midbrain lesion. Bilateral blindness with non-reacting pupils must be due to a lesion between the retina and the first part of the optic tract, for after that the pupillary constrictor fibers have left the visual fibers.

4-Light-near dissociation. Impaired pupillary reaction to light with preserved constriction during accommodation is usually bilateral and may result from neurosyphilis, diabetes, optic nerve disorders, and tumors compressing the midbrain tectum, meningo-radiculitis and Lyme disease.

5-Argyll-Robertson pupils. These pupils are small, irregular in shape, unequal in size and show light near dissociation. Neurosyphilis is the usual cause. The site of the lesion is not certain. Some favor the tectum of the midbrain, others, the ciliary ganglion, but bearing in mind the nature of the neurosyphilitic lesions, multiple sites can not be excluded. Other causes of AR pupil include diabetes mellitus, orbital injury, hereditary neuropathies and sarcoidosis.

6-Marcus Gunn pupil (relative afferent pupillary defect). In this condition, one pupil constricts less markedly in response to direct illumination than to illumination of the contralateral normal pupil, whereas normally the direct response is greater than the consensual response. If a light is shifted quickly from the normal to the impaired eye, the direct light stimulus is no longer sufficient to maintain the previously evoked consensual pupillary constriction and both pupils dilate. These abnormal pupillary responses form the basis of the

swinging flash-light test in which each pupil is alternatively exposed to light at 3-5 seconds interval. Relative afferent papillary defect is commonly associated with disorders of the ipsilateral optic nerve which interrupt the afferent limb and affect the pupillary light reflex.

Squint

Squint is deviation of the eye from the optical axis. It is of two types:

- 1- Concomitant (non-paralytic) squint: In this condition, there is muscle imbalance, but the ocular movements are full and the squint may be divergent or convergent. There is no diplopia as faulty image has been neglected by the patient. The commonest cause of this condition is uncorrected error of refraction in childhood.
- 2- Non concomitant (paralytic) squint: It results from paralysis of the one or more of the ocular muscles commonly due to lesions of the third, fourth, or the sixth cranial nerves and is characterized by limitation of eye movements and increasing diplopia in the field of action of the paralyzed muscle.

Third nerve palsy

It is characterized by the following (4 Ds) features:

- 1- Drooping of eyelids (ptosis).
- 2- Divergent squint.
- 3- Diplopia.
- 4- Dilated pupil.

Localization of lesions. It depends on the associated clinical signs. The nerve may be involved at nuclear, fascicular, sub-arachnoid space, cavernous sinus, superior orbital fissure, or orbital sites (Table 8) & (Figure 4). Look also to the pictures below.

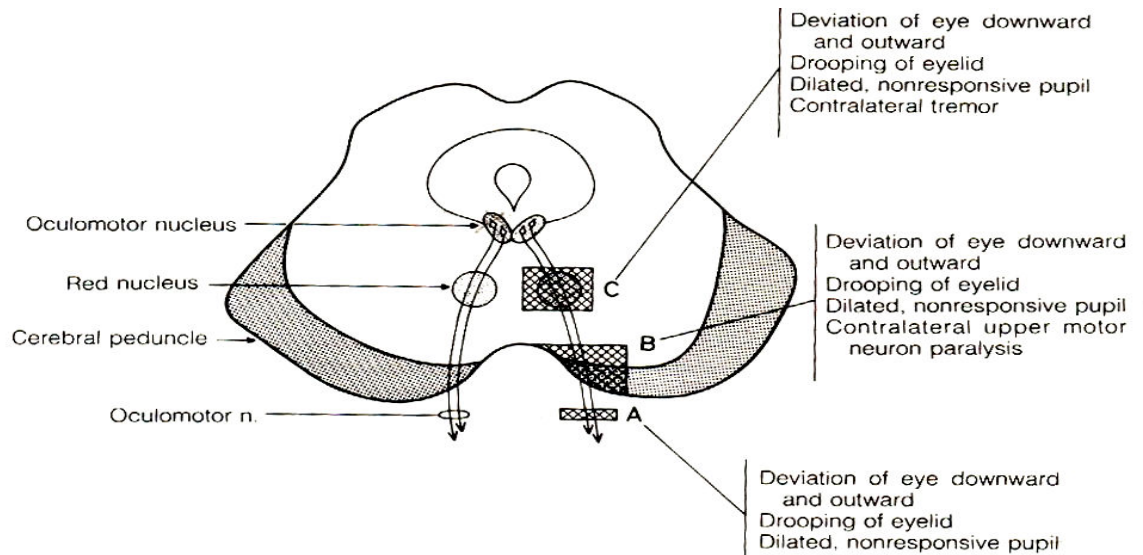


Figure 4: Schematic diagram showing lesion of the oculomotor nerve in its intra and extra-axial course and their respective clinical manifestation

Sixth nerve palsy

It is characterized by the following features:

- 1- Convergent squint (in turning of the eye)—failure of abduction of the eye.
- 2- Diplopia in the primary position and on looking toward the direction of the paretic muscle.
- 3- Compensatory head tilt towards the side of the lesion.

Localization of the lesions

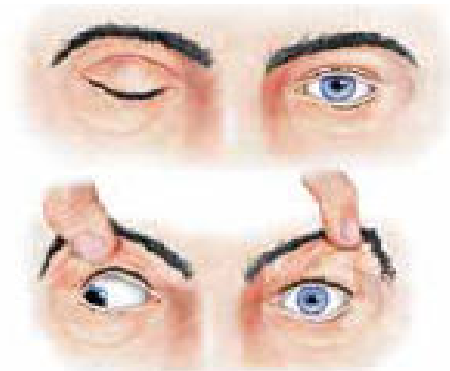
This nerve might be implicated at nuclear, pontine (fascicular), pre-pontine cistern (sub-archnoid space), petrous portion (Dorellos canals), cavernous sinus, superior orbital fissure or orbital. For localization and causes of sixth nerve palsy, look at table (9) and picture below.

Fourth nerve palsy


It is characterized by the following features:

- 1- The affected eye tends to deviate upward and inward.
- 2- Vertical diplopia: The patient complains of difficulty in reading and on going downstairs.
- 3- Extortion and weakness of downward movement of the affected eye when the eye turned inward.

- 4- Head tilting to the opposite shoulder to obtain single vision when looking forward.
- 5- In the presence of third nerve palsy, there is failure of intorsion as the patient tries to move the paretic eye downward.



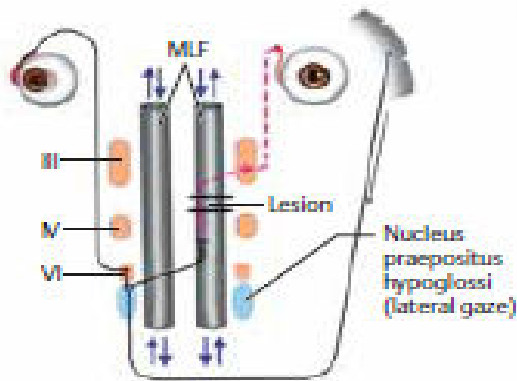
Complete right oculomotor palsy
(looking straight ahead)



Right trochlear palsy (looking straight ahead)

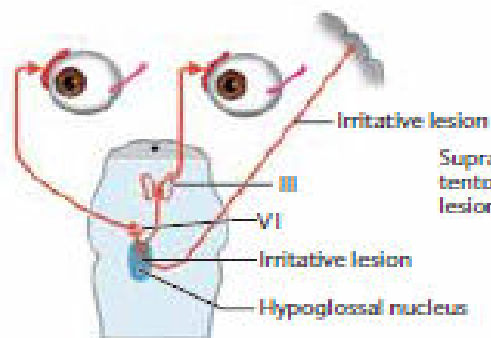


Abducens palsy (looking straight ahead)

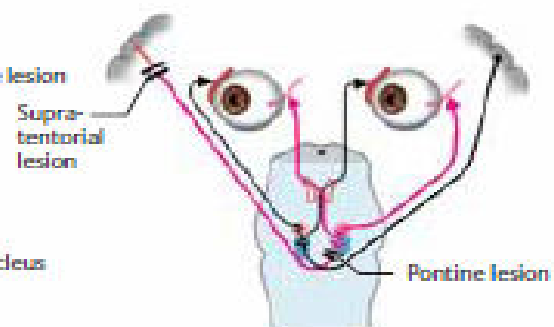


Neuroanatomy of internuclear ophthalmoplegia (INO) (shown: left INO on rightward gaze)

Bilateral INO
(leftward, rightward, and downward gaze)



Rightward gaze deviation
(irritative lesion: left, supratentorial; right, pontine)



Conjugate supranuclear paresis of leftward gaze
(right supratentorial lesion or left pontine destructive lesion)

Table 8. Localization of lesions involving the third cranial nerve

	Site	Characteristic features	Common causes
1-	Nuclear lesions	Weakness of all ipsilateral muscles, contralateral superior rectus muscle and bilateral partial ptosis.	Infarction, hemorrhage, demyelination, intrinsic tumors.
2-	Fascicular lesions	Sparing of the contralateral eye plus involvement of brainstem structures other than the fascicles of the third nerve helps in identifying the extent and location of the lesion.	The same above causes.
3-	Sub-arachnoid's space lesions	Usually causes isolated third nerve palsy.	Aneurysm, uncal herniation, GBS, tumors, meningitis, neurosurgical procedures.
4-	Cavernous sinus	Painful ophthalmoplegia, fourth, sixth and first branch of the fifth nerve may be involved.	Tumors, infection, inflammation, thrombosis, metastasis, aneurysm.
5-	Superior orbital fissure	The same features of cavernous sinus lesions plus proptosis, if due to space occupying lesions.	The same causes as mentioned above for cavernous sinus lesions
6-	Orbital lesions	Isolated involvement of muscles innervated by either superior or inferior oculomotor branch with optic nerve involvement.	Trauma or tumors.

Table 9. Localization of lesions involving the sixth cranial nerve

	Site	Characteristic features	Common causes
1-	Nuclear lesions	Ipsilateral lateral rectus paresis plus horizontal gaze palsy to the same side.	Ischemic.
2-	Fascicular lesions	Ipsilateral abducent and facial weakness with contralateral hemiparesis.	Often ischemic, but may be tumors, plaques, granulomas, or lesions of Wernicke's encephalopathy.
3-	Sub-arachnoid space lesions	Usually isolated sixth nerve palsy, but could be associated with contralateral hemiparesis with or without facial pain (ipsilateral) due to compression of the trigeminal root.	Increased intracranial pressure, aneurysm, meningioma of the clivus chordomas, naso-pharyngeal carcinoma, trauma, chronic meningitis, GBS.
4-	Petrous portion of Sub-arachnoid space lesions	A concomitant involvement of the trigeminal nerve, otic discharge from chronic otitis media or mastoiditis, or deafness called "Gradenigo syndrome ". Sixth, fifth, and eighth cranial nerves.	Infection, tumors, trauma.
5-	Cavernous sinus	Retro-orbital pain, involvement of other ocular motor nerves and occasionally an ipsilateral Horner's syndrome.	Pituitary adenomas, nasopharyngeal carcinoma, craniopharyngioma, metastasis, Tolosa-Hunt syndrome.
6-	Superior orbital fissure	The same features plus proptosis, if due to space occupying lesions.	The same as above causes.
7-	Orbital lesions	Isolated sixth nerve palsy.	Trauma, tumor, inflammatory process.

Table 10. Localization of lesions affecting the fourth cranial nerve.

	Site	Characteristic features	Common causes
1-	Dorsal midbrain	Fourth nerve palsy plus upward gaze palsy	SOL
2-	Anterolateral midbrain	Ipsilateral cerebellar signs due to involvement of the superior cerebellar peduncle	SOL, tentorial meningiomas
3-	Anterior midbrain	Contralateral hemiparesis, predominantly involving the leg.	Ischemic
4-	Cavernous sinus	Involvement of other ocular nerves (the third, the fourth, the sixth, and the first division of the trigeminal nerve with subsequent retro-orbital pain.	Cavernous sinus pathology (aneurysm, thrombosis).
5-	Superior orbital fissure	The same features plus proptosis if due to SOL	Tumor, granuloma
6-	Orbital lesions	Isolated fourth nerve palsy.	Trauma

Gaze palsies

Conjugate gaze palsies

A conjugate gaze palsy is one in which both eyes are symmetrically restricted in their movement to one side, up or down.

Horizontal gaze palsy

Unilateral restriction of voluntary gaze to one side is usually due to contralateral frontal or ipsilateral pontine damage.

Frontal lesions are characterized by the following features:

- 1- Tend to be rather acute, and the resultant palsy is usually transient.
- 2- The patient looks toward the lesion and away from the hemiparesis.

- 3- The eyes can be brought toward the paretic side by using the oculocephalic reflex, (doll's eye maneuver).
- 4- Infranuclear muscle paralysis is not present, so diplopia is never present.
- 5- The above features are characteristic of destructive lesions. Epileptogenic lesions may cause transient deviation of the eyes and head to the contralateral side (the patient then looks away from the lesion). However, in most cases, as soon as the focal seizure ceases, the patient tends to look to the involved side.

Pontine lesions are characterized by the following features:

- 1- The eyes look toward the hemiparetic side which is an inconsistent finding.
- 2- The eye can not be brought to the gaze paretic side using the doll's maneuver or ipsilateral cold caloric stimulation.
- 3- Infranuclear muscle paralysis is often present, diplopia is not uncommon.
- 4- Gaze palsy is present as long as the lesion remains.

Vertical gaze palsy

- Vertical eye movement is under control of bilateral cerebral cortex and upper brain stem.
- The group of nerve cells and fibers that govern the vertical gaze are situated in the pretectal area of the midbrain.
- The vertical gaze center involves three integral structures: the rostral interstitial nucleus of the medial longitudinal fasciculus (riMLF), interstitial nucleus of Cajal (INC), and nucleus and fibers of posterior commissure.
- Vertical gaze palsies are almost always caused by lesions in the rostral midbrain near the area of the (riMLF).
- The lesions must be either bilateral or involve the crossing posterior commissure fibers. The medial portion of the riMLF is mainly devoted to down gaze whereas the lateral portion subserve up gaze. The lateral fibers course medially in the nucleus and cross in the posterior commissure before traveling in the MLF.

- Bilateral medial riMLF lesions can produce isolated down gaze palsies, whereas a lesion in the posterior commissure can produce both up and down gaze palsies.

Up gaze palsy

- This condition results from lesions in the pretectal region, usually with damage to the posterior commissure.
- Lesions in this area is called Parinaud's syndrome or Sylvian aqueduct syndrome, which include in addition to upward gaze palsy, other ocular findings as well (lid retraction, ptosis, light-near dissociation and convergence retraction nystagmus).
- Common causes include: Tumors and hydrocephalus.
- Less likely causes include: Cerebral hemorrhage or infarction, multiple sclerosis, trauma, lipid storage disease, Wilson's disease, Whipple's disease, syphilis and tuberculosis.

Down-gaze palsy

- Damage to the riMLF and its projections to the third nerve nuclear group and the fourth nerve nucleus is probably the site of the lesion.
- Infarcts in the territory of the paramedian thalamomesencephalic artery, a proximal branch of the posterior cerebral artery represent the most common cause.
- Down-gaze is involved early in progressive supranuclear palsy.

Disconjugate gaze palsies

Horizontal gaze palsy

- 1- The Medial longitudinal fasciculus syndrome or the internuclear ophthalmoplegia (INO). Clinically, this syndrome is characterized by adduction weakness on the side of the MLF lesion and nystagmus of the abducting eye. However, unless the lesion is quite high, reaching the midbrain, convergence is preserved. Bilateral INO is most often seen with multiple sclerosis. Unilateral INO may result from infarction. Other causes include Wernicke's encephalopathy, trauma, and encephalitis. The pattern of

extraocular muscle weakness in myasthenia gravis and post infectious neuritis can mimic INO.

- 2- The "one and a half" syndrome: In these cases combined unilateral horizontal gaze palsy and INO will present. There is a conjugate gaze to one side (one) and impaired adduction on looking to the other side (one and a half). As a result, the only horizontal movement remaining is abduction of one eye which exhibit nystagmus in abduction. Vertical movement and convergence are spared. The responsible lesion involves the para-pontine reticular formation (PPRF) and the adjacent MLF on the side of the complete gaze palsy. This syndrome is most often caused by multiple sclerosis, infarctions, hemorrhage and tumors.

Vertical gaze palsy (skew deviation)

It means vertical misalignment of the eyes. It can accompany lesions at different areas of the brainstem.

- 1- Peripheral vestibular disease: the contralateral eye is higher than the ipsilateral eye.
- 2- Vestibular nuclei (lateral pontomedullary lesion): the lower eye is on the side of the lesion.
- 3- MLF lesions: The eye on the side of the lesion tends to be higher.
- 4- Posterior commissure: The ipsilateral eye is higher or there is slowly alternating skew deviation in irregular period lasting from 10-60 seconds.

Diplopia

Diplopia can detect ocular muscle weakness before it is visible to the examiner. The light rays fail to fall on exactly corresponding points of the two retinae, and a false image is formed which is usually paler and less clear. The rules governing the relationship of these two images are as follows:

Rule I: Displacement of the false image may be horizontal, vertical, or both.

Rule II: separation of the images is greatest in the direction in which the weak muscle has its purest action.

Rule III: The false image is displaced furthest in the direction in which the weak muscle should move the eye.

Methods of examination

Cover one eye of the patient with transparent red shield, do ocular movement as discussed previously. In each of the seven positions ask the patient:

- 1- Whether he sees one object or two.
- 2- If double, do the two image lie side by side, or one above the other?
- 3- In which position are they furthest apart.
- 4- Which is the red image?

Interpretation of the results

If the images are exactly side by side, it will be only the internal or the external recti that are involved. If they are one above the other, either of the obliques, or the superior and inferior recti may be defective.

The muscle pair involved?

It is the position in which there is maximum displacement which indicate which pair of muscles is involved (Rule II), e.g. if maximum displacement occurs when the eyes are deviated to the right and upwards, this is the movement carried out by the right superior rectus and the left inferior oblique.

The individual muscle responsible?

To determine which of the two muscle in each pair is defective, the patient must say which of the two images is displaced furthest, the red or the white. Using the same example, if the red glass were over the right eye, and on looking to the right and upwards the red image is furthest displaced, then it must be the muscle moving the eye in that direction (Rule III), namely, the superior rectus, that is at fault. If it were the white image that was furthest displaced the fault would be with the left inferior oblique.

It is good exercise to work out the situation in each direction for each possible muscle fault, and the more frequently this is done, the easier it becomes. In practice, off course, multiple faults occur, and particularly when the

third nerve is involved, it is at times easier to work out which muscles are acting normally.

Various charts exist for representing diplopia diagrammatically, of which the Hess chart and those used in orthoptic analysis are the most useful. They do not, however, offer better evidence than is offered carefully following the scheme of combination just described.

Causes of diplopia

- 1- Nuclear lesions of the ocular nerve: Caused by ischemia, demyelination, infection, trauma, and tumors. Usually diplopia is associated with other brainstem signs like long tracts signs, ataxia, and disturbances in the level of consciousness ...etc.
- 2- Ocular motor nerve: The pattern of double vision, along with any associated features, usually allows localization of the lesion, discussed previously.
- 3- Neuromuscular junction: It can cause diplopia by affecting any or all of the extraocular muscle. It is often associated with ptosis and the hallmark is fatigability.
- 4- Muscle: Diseases of the extraocular muscles themselves can cause diplopia. Such diseases include thyroid eye disease, myopathies, and orbital myositis. The mode of onset and subsequent behavior suggest the etiology.

Nystagmus

The balance of tone between opposing muscles is maintained by impulses from the retina, the ocular muscles, the vestibular nuclei and their peripheral and central connections, and by the proprioceptive impulses from the neck muscles. It is normally so maintained that the eyes at rest remain at the midline. Any disturbances of this balance results in a drift of the eyes in one or other direction. If this drift is then corrected by, a quick movement back to the original position, and this cycle is repeated frequently, nystagmus results.

Purposes of tests

- 1- To detect and analyze nystagmus (its direction, rate and amplitude).

- 2- To know from its character whether it has any anatomical localizing value or not.

Methods of testing

- 1- Watch patient's eyes at the primary position. Nystagmus on forward gaze can be noted at once.
- 2- During ocular movement look for any gaze evoked nystagmuses.

Types of nystagmus

1-Pendular nystagmus

A rapid horizontal oscillation to either side of the midline, of equal amplitude, but variable speed, present and usually obvious on forward gaze, increased by fixation, but often losing its Pendular character on lateral deviation. It is important to avoid unnecessary investigations in these patients.

Causes:

- A- Visual failures from earlier years, including macular degenerations, choroidoretinitis, albinism, high infantile myopia, opacities of the media, miners.
- B- Congenital nystagmus: It is also Pendular and horizontal but becomes "jerky" on lateral gaze and remain horizontal on up-gaze and down-gaze. Congenital nystagmus is a benign finding, which result from an arrested process occurring early in the life. One variety of congenital nystagmus called latent nystagmus that appears when one eye is covered.

2- Jerk nystagmus

The rhythm of this common type of nystagmus is that of slow drift in one direction and a fast corrective movement in the other. It may be present at rest or only on ocular deviation. Jerk nystagmus may be horizontal, vertical, or rotatory.

- a- **Horizontal nystagmus.** It is a to-and-fro movement in the horizontal plane, no matter in which direction the eyes may be deviated to demonstrate it.

Causes

It is produced by disturbances of the vestibulo-ocular pathways. These may occur peripherally in the labyrinth, centrally at the nuclei, in the connection between these (the vestibular nerve), or between the nuclei and the ocular muscles (the median longitudinal bundle). It is seen in lesions of the cerebellum due to involvement of the cerebello-vestibular connections, and in lesions of the uppermost cervical region.

- 1- In peripheral vestibular lesions: The quick phase is away from the lesion, and the amplitude is greater in the direction of the quick phase. Peripheral lesions are usually had additional vertigo, tinnitus and deafness, such as menier's disease, and acoustic neuroma. Though the later cause may produce central effects as well.
- 2- Central vestibular lesions: These tend to be more chronic, may cause no tinnitus or deafness and vertigo is less constant. Examples include multiple sclerosis, vascular lesions, or tumors of the cerebellum, fourth ventricle and cerebello-pontine angles (when the fifth and the seventh nerves may also be involved). Two main differences identify peripheral from central vestibular nystagmus. First-fixation suppresses peripheral but not central nystagmus, second- peripheral nystagmus, particularly when vertical, has a torsional component but pure vertical or torsional nystagmus is usually central.
- 3- Cerebellar lesions and disturbances of its brain stem connections: The quick phase and the greatest amplitude are towards the side of the lesion. It is a gaze evoked nystagmus. Cerebellar hemisphere lesions also cause ocular dysmetria.
- 4- Cerebello-pontine angle lesions: these cause Burns's nystagmus, a combination of ipsilateral large amplitude, low frequency nystagmus that is due to impaired gaze holding (cerebellum), and a contralateral small amplitude, high frequency nystagmus that is due to vestibular impairment (central) i.e. both central and peripheral effect, but the

amplitude is greater toward the side of the lesion. It is gaze evoked nystagmus.

- b- **Vertical nystagmus.** In this condition the oscillation of the eye is in an up and down direction, no matter what the position of the eye. It is seen on looking upward or downward. It is due to intrinsic disturbances of the brainstem. It is never labyrinthine in origin. Causes of vertical nystagmus include the following: Vascular accidents, encephalitis, multiple sclerosis, syringobulbia, and secondary to compression from cerebellar diseases such as tumors, basilar invagination with tonsillar descent and the Arnold-Chiari syndrome. However, drugs remain the commonest cause of vertical nystagmus. Benzodiazepines, barbiturates, and phenytoin are often responsible.
- c- **Rotatory nystagmus.** This type of nystagmus may occur in both peripheral (labyrinthine) and central (brainstem) diseases. In peripheral disorders, it is usually at the acute stage, transient, and it is not purely torsional i.e. horizontal, or vertical with torsional component. If long standing, it indicates disease of the vestibular nuclei, especially the inferior portion. It is usually pure torsional.

Causes:

Any of the disorders causes' vertical nystagmus can be included here.

Other important types of nystagmus:

1- **Ataxic nystagmus**

It occurs in an internuclear ophthalmoplegia due to a lesion in the median longitudinal fascicle. There is defective inward movement of the adducting eye with a fine nystagmus, accompanied by a coarse, irregular, rather dramatic nystagmus of the abducting eye, of the dissociated rate and rhythm. Ataxic nystagmus may be mimicked by asymmetrical muscle weakness in myasthenia gravis.

2- Beating nystagmus

It is seen in the primary position of a conscious patient. Down-beating = downwards, up-beating= upwards.

- a- Down-beat nystagmus. It often accompanies posterior fossa lesion near the cranio-cervical junction, such as Arnold-Chiari malformation, tumors, and multiple sclerosis. Defective drive by posterior semicircular canals, whose central projections cross in the floor of the fourth ventricle, has been postulated as an explanation for this type of nystagmus.
- b- Up-beat It is seen in lesions of higher position in the ponto-medullary junction, which cause damage to the central projections of the anterior semicircular canals, which tend to deviate the eye superiorly. Causes include: anterior vermal cerebellar lesion, diffuse brainstem lesion, lesions of inferior olivary nuclei, Wenricke's encephalopathy, drugs intoxication and meningitis.

3- See saw nystagmus

It refers to the cyclic movement of the eyes, while one eye rise and intorts, the other falls and extorts; the vertical and tortional movement are then reversed, completing the cycle. Responsible lesions are generally in the inferior portion of the third ventricle (parasellar tumors) or midbrain infarction. The interstitial nucleus of Cajal may play a role in the production of this type of nystagmus.

4- Convergence-retraction nystagmus

Attempted up gaze, usually defective, provoke a jerk nystagmus with the fast phase inwards, in a convergent manner. This type of nystagmus may occur spontaneously or by sliding an optokinetic tape downwards in front of the patient's eyes. Mesencephalic lesions affecting the pre-tectal region are most likely to cause this type of nystagmus. Pressure on the pre-tectal area by a nearby pineal body tumors, hydrocephalus may also lead to it.

5- Periodic alternating nystagmus

Periodic alternating nystagmus can be congenital but it is often acquired and has a localizing value similar to that of downbeat nystagmus, pointing to a possible disease at the cranio-cervical junction. The eyes exhibit the primary position nystagmus, which after 60-90 seconds, stops for a few seconds and then start beating in the opposite direction. A few beats of the downbeat nystagmus may appear in the interval between alternating side beat nystagmus. This type of nystagmus has been described with tumors, trauma, encephalitis, multiple sclerosis and vascular disease.

6- Lid nystagmus

This refers to eye lid twitches that are synchronous with the fast phase of horizontal nystagmus. It has been described in lateral medullary disease.

7- Rebound nystagmus

It is seen in some patients with cerebellar disease. After keeping the eyes eccentric for sometime, the original gaze evoked nystagmus may wane and actually reverse direction, so that the slow component is directed centrifugally and it becomes obvious if the eyes are returned to mid-position.

8- Gaze evoked nystagmus

In this disorder, the eyes fail to remain in an eccentric position of gaze, but drift to mid-position. The velocity of the slow phase decreases as the eyes approach mid-position. It includes many types of nystagmus that have been discussed previously, like, cerebellar lesions, brainstem lesions, cerebello-pontine angle tumors, and median longitudinal fascicle lesions.

Types of cerebellar nystagmus (revision)

1- Opsoclonus

Rapid, conjugate, irregular, continuous oscillation of the eyes in horizontal, Rotatory and vertical directions, made worse by voluntary movement or the need to fixate the eyes.

Causes:

- a- Encephalitis in children (dancing eyes).
- b- They could be as a part of wide spread myoclonus (associated with para-infectious diseases and with para-neoplastic syndrome).
- c- Drug intoxication: antidepressants, anti-epileptics, organo-phosphorus, lithium, thallium.
- d- Non-ketotic hyperosmolar state.
- e- Neuroblastoma of children.
- f- Self limited benign opsoclonus in neonates.

2- Ocular flutter

Occasional bursts of very rapid, regular, oscillations around the point of fixation.

3- Ocular dysmetria

It consists of an overshoot of the eyes on attempted fixation, followed by several cycles of oscillations, of diminishing amplitude, until precise fixation is reached.

4- Rebound nystagmus. This is the most specific type for cerebellar diseases.

5- Bruns's nystagmus

Occur in cerebello-pontine tumors, I had been discussed previously.

6- Ocular cog-wheeling:

This is an interrupted gaze due to impairment of the smooth pursuit movement.

Optokinetic nystagmus (OKN)

Optic nystagmus is a normal phenomenon, best obtained when sitting opposite some one in rail way carriage. It can be obtained by passing before the eyes a tape marked with black and white squares, first in one direction, then in the other. In deeply parietal lesion the OKN is absent or much reduced when the tape is rotated towards the side of the lesion. An important fact about OKN is that it's demonstration proves that the patient is not blind. Thus it is of particular value in the examination of hysterical patients and malingerers who claim that they can not see and of neonates and infant (OKN) is established within minutes or hours after birth.

2-4: The Fifth Cranial Nerve (The trigeminal nerve)

Functions

The important functions are:

- a- It carries all forms of sensation from the face, the anterior part of the scalp, the eye and the anterior two thirds of the tongue.
- b- It gives motor power to the muscle of mastication (Figure 5).

Purposes of the tests:

- a- To determine whether the motor weakness is unilateral or bilateral, and of upper or lower motor type.
- b- To determine which, if any, of the modalities of sensation are impaired.
- c- To decide from the pattern of the sensory loss whether the lesion lie in one of the peripheral branches, in the Gasserian ganglion, sensory root or the brainstem.

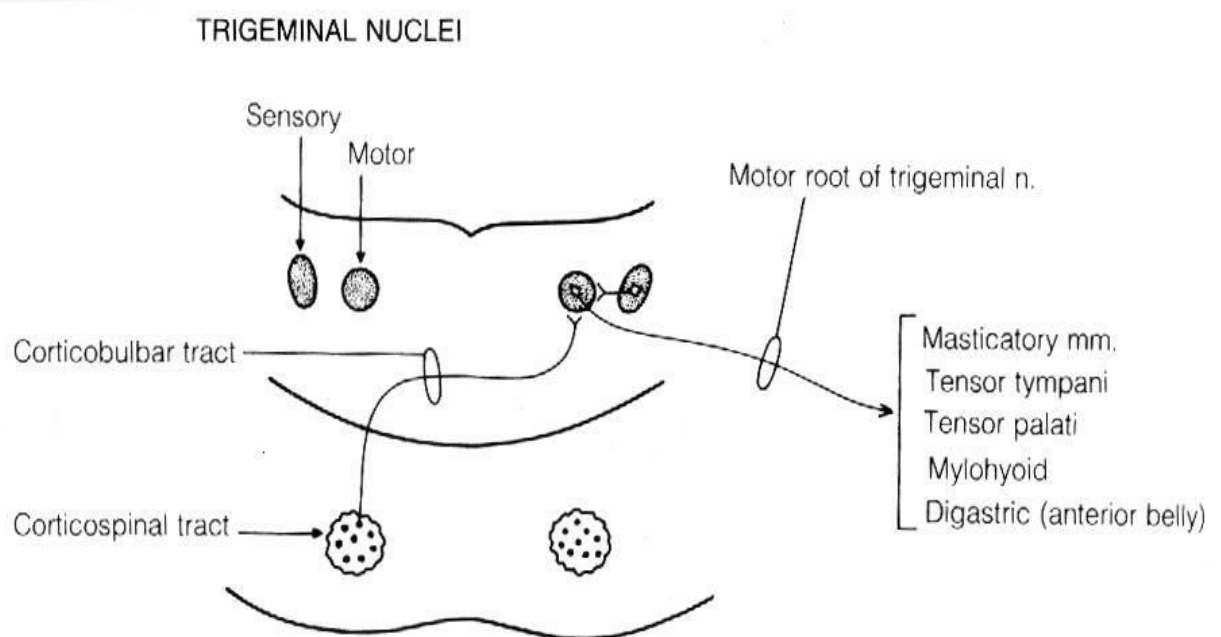


Figure 5: Schematic diagram showing the origin, intrapontine course and muscles supplied by the motor division of the trigeminal (CN V) nerve

Methods of examination

1- Motor part:

The temporal muscles, masseters and ptergoids are tested.

- a- Inspect the symmetry of the temporal fossa, and the angle of the jaw.
Look for any wasting or fasciculation of these muscles.
- b- Palpate these muscles at rest, and then ask the patient to clench his teeth and compare these muscles on both sides as they stand out as hard lumps.
- c- Ask the patient to open his mouth at rest, and then against resistance by placing your hand under the jaw. Look for any jaw deviation.

2- Sensory part

Pain, light touch and temperature are the main modalities examined. Six areas on each side are tested, near, but not, at the midline:

- a- The forehead and the upper part of the side of the nose (ophthalmic division).
- b- The malar region and upper lip (maxillary division).
- c- The chin and anterior part of the tongue (the mandibular division).

Lastly do not forget to examine pain sensation of the face from midlines towards periphery for onion skin pattern of sensory loss, which reflects the rostral-caudal somatotopic arrangement of the cutaneous distribution of spinal nucleus (like peri-oral-rostral –lateral face-caudal).

3- Reflexes

- a- The corneal reflex:
 - i- Explain the test to the patient.
 - ii- Ask the patient to look upward as much as he can, in order to widen the palpebral fissure.
 - iii- A piece of cotton-wool teased to a point is touched just lateral to the pupil on either side.
 - iv- Normally there is bilateral blink, whichever side tested. The facial nerve forming the efferent loop of the reflex arc.
 - v- The jaw jerk:

- vi- Ask the patient to let his jaw sag; open slightly, but not to open it wide.
- vii- The examiner then places the left forefinger below the lower lip and taps it in a downward direction with the percussion hammer.
- viii- The normal response is either slight palpable upward jerk, or no response is obtained.

Results of examination

a- Motor abnormalities

- 1- Unilateral upper motor neuron lesions: Lesions interrupting cortico-bulbar fibers to the contralateral motor nucleus of the trigeminal nerve result in contralateral trigeminal paresis, e.g. deviation of the jaw away from the lesion, but because of the bilateral innervations, paresis is mild.
Causes: Stroke, demyelination, trauma...etc.
- 2- Bilateral upper motor weakness:
This is a part of the pseudobulbar palsy. It results in profound trigeminal paresis, often with exaggerated jaw reflex. Mastication is markedly impaired.
- 3- Unilateral lower motor neuron weakness:
It leads to ipsilateral paresis, atrophy and fasciculation of the muscle of mastication. Jaw deviates to the side of the lesion. Corneal reflex is depressed. It is usually caused by nuclear lesions in the Pons, or lesions involving the root of the trigeminal nerve.
- 3- Bilateral lower motor neuron weakness:
It leads to bilateral paresis, atrophy, and fasciculation of the muscles of mastication. Jaw and corneal reflexes are diminished. This may be caused by nuclear lesions as in the motor neuron disease or muscular dystrophy.

b- Sensory abnormalities

- 1- Total sensory loss over the whole distribution of the nerve:
This indicates a lesion in the ganglion or sensory root. If it is part of total hemianesthesia, the lesion is in the opposite thalamus. Common causes include: Tumors eroding the base of the skull, large neuro-fibromata of

the fifth and the eighth cranial nerves, epidermiod, chronic meningeal lesions as sarcoid, tuberculosis or syphilis and basal injuries.

2- Total sensory loss over one or more of the main divisions:

This can be found in partial lesions of ganglion, e.g. herpes zoster, or the root, e.g. acoustic neuroma. More peripherally, the ophthalmic division is involved in the cavernous sinus by carotid aneurysms and in the orbital fissure by tumors. The maxillary division is rarely involved alone except as a result of trauma, but it is also affected in the cavernous sinus, while basal tumors involve the mandibular division usually affecting the motor root as well.

3- Touch is only lost

This is a pontine lesion affecting the principal sensory nucleus, and is usually due to vascular disease, to pontine tumors, or to brainstem displacement by large tumors.

4-Pain and temperature are lost, but touch is preserved:

Dissociated anesthesia results from a lesion in the descending root and occurs in syringobulbia, foramen magnum tumors or anomalies, and bulbar vascular accident as in Wallenberg's syndrome.

5-Hyperesthesia over whole or part of the distribution of the nerve:

It indicates irritative rather than destructive lesion. It gives little localizing value. It is most common in vascular lesions and herpes and least common in syringomyelia.

c- Reflex abnormalities

1- The corneal reflex

If there is no response on one side, this may be due to a lesion of the sensory (ophthalmic division) or motor side (the facial nerve) of the reflex arc.

In cases of fifth cranial nerve lesions, there will be no response from both eyes when the abnormal side is stimulated and a normal response from both eyes when the normal eye is stimulated.

In cases of seventh nerve lesions, there will be no response from the side of the facial nerve palsy, no matter which side is stimulated. But, providing the fifth nerve is intact, there will be a blink on the normal side even when the abnormal side is touched and both eyeballs can be seen turn upwards.

2- The jaw jerk

a- Absent jaw jerk: This is rarely helpful.

b- Exaggerated jaw jerk: This indicates lesion above the level of the pons. This is commonly seen in pseudobulbar palsy due to motor neuron disease, multiple sclerosis and multiple cerebral infarctions.

Brisk jaw jerk make the lesion above the spinal level, if you find exaggerated reflexes in the arm and the leg.

Localization of lesions

Fifth cranial nerve may be implicated at the pons, medulla oblongata, cerebello-pontine angle, Gasserian ganglia, cavernous sinus, superior orbital fissure, maxillary sinus and infra temporal fossa . The common causes and their clinical feature at these sites are shown in Table (11)

Table 11. Localization of lesions affecting the fifth cranial nerve

Site of the lesion	Example	Clinical features
Pons (motor and sensory nuclei)	Infarction, DS, tumors, AVM	Motor and sensory functions of the fifth nerve are affected. Brainstem signs (e.g. long tract signs, other cranial nerves involvement, and so on)
Medulla Descending spinal nucleus	Infarction, syrinx	Loss of temperature and pain sensation on the face. Dissociated sensory loss, contralateral loss of pain and temperature. Onion skin pattern of sensory loss. Other brainstem signs.
Preganglion fifth nerve root lesions (motor and sensory)	Tumors, infection, trauma, aneurysm, SLE, scleroderma, cerebello-pontine angle tumors	Ipsilateral facial pain, numbness and sensory loss plus motor involvement plus affection of the neighboring cranial nerves, especially the sixth, seventh, and the eighth cranial nerves.
Gasserian ganglion	Lesion of the middle cranial fossa (tumor, herpes zoster, trauma, abscess)	All of the three sensory divisions may be involved. Trigeminal neuralgia. Motor part also may be involved. Other cranial nerves especially 6 th nerve may also be affected.
Cavernous sinus	Aneurysm Thrombosis	Ophthalmic division is affected, corneal reflex is impaired. Other ocular nerve involvement including 6 th , 3 rd , and 4 th cranial nerves. Less often the maxillary division of the 5 th cranial nerve may be involved.
Superior orbital fissure	The same above causes	The same features as mentioned above with or without exophthalmos.
Maxillary sinus	Antral carcinoma	Maxillary division is affected.
Infra-temporal fossa	Nasopharyngeal carcinoma	Mostly the mandibular division is involved with sensory and motor involvement.

2-5: The Seventh Cranial Nerve (The Facial nerve)

Functions (Figure 6)

- 1- **MOTOR:** Motor supply of muscles of expression and facial movement including the platysma and the stapedius.
- 2- **SENSORY:** Taste sensation from the anterior 2/3 of the tongue (chorda tympani nerve).
- 3- **SECRETOMOTOR:** Lacrimation and salivation.

Purposes of the tests:

- 1- To determine whether any facial weakness detected is unilateral or bilateral, and whether it is of upper or lower motor neuron type.
- 2- If the weakness is of upper motor neuron type, to determine whether it is voluntary or emotional type.
- 3- To detect impairment of taste, Lacrimation and salivation.

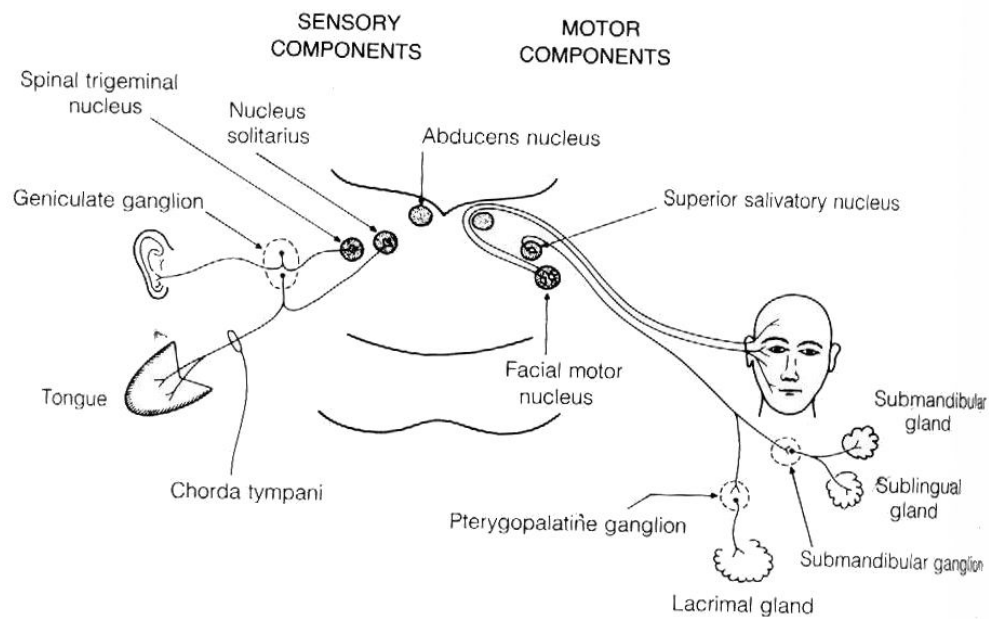


Figure 6: Schematic diagram showing the nuclei of origin, course, and areas of supply of the Facial (CN VII) nerve

Methods of examination

I- Motor supply to muscles of expression

Look for any facial asymmetry at rest then test:

- a- Frontalis muscle: ability to wrinkle forehead and lift eyebrows (look up at ceiling).
- b- Orbicularis oculi: test ability to shut eyes tightly, try to forcibly open eyes.
- c- Orbicularis oris: ask the patient to show his teeth, look for nasolabial fold and the mouth angle.
- d- Platysma: ask the patient to bare his teeth and to open his mouth at the same time.
- e- Other movements, such as whistling, blowing out the cheeks...etc, can be used as confirmation of the strength or weakness, but do not usually give additional information.

II- Examination of taste

Ask the patient about any recent change or loss of taste sensation. Also ask him about any abnormal taste sensation or hallucinations of taste. These may form the aura of an epileptic fit, especially temporal lobe epilepsy. Conventional examination of taste with the four primary tastes (sweet, salt, sour, and bitter) is time consuming, needs cooperative patient and it is not routinely recommended.

III- Examination of the sensory function

- The flow of tears on the 2 sides can be compared by giving the patient ammonia to inhale.
- The flow of saliva is compared by placing a highly spiced substance on the tongue and asking the patient to raise the tip.
- These tests are not often required and the patient is usually able to describe any defects spontaneously.

Results of examination

Types of facial weakness

- 1- Unilateral emotional paralysis: Deviation of the mouth on smiling, which disappears on voluntary movement. This occurs in deep seated lesion of the opposite globus pallidus, thalamus, and hypothalamus or its connection with the frontal lobe. It can be caused by neoplasm or vascular accident.
- 2- Unilateral upper motor neuron paralysis: Weakness of the lower face (deviation of the mouth and deepening of the nasolabial fold) with normal eye closure and forehead wrinkling. This is due to a lesion at some point between the opposite cortex and the facial nucleus in the pons. The upper facial muscle on each side are controlled by both cerebral cortices, so that if one cortico-bulbar pathway is damaged the other is still capable of performing its function. An associated hemianopia will mean a hemisphere lesion, any hemiplegia will be on the same side. It can be caused by either cerebrovascular disease or cerebral tumor.
- 3- Unilateral lower motor neuron weakness: both upper and lower parts of the face are equally involved. The eye can not be closed or can easily be opened by the examiner. The eyeball is seen to turn upward on attempted closure (Bell's phenomenon), the patient does not blink on that side and the normal wrinkling on that side of the forehead is absent. A lesion inside the facial canal may cause paralysis of stapedius muscle, so the sound on the affected side perceived unusually loud (hyperacusis). See pictures below.

Causes:

- a- Intracranial
 - i- Pontine lesions (infarction, demyelination)
 - ii- Cerebellopontine angle lesions.
 - iii- VII neuroma or neurofibroma.
- b- During the passage through temporal bone
 - i- Fractures.
 - ii- Surgical procedures.

iii- Otitis media.

iv- Middle ear carcinoma.

v- Ramsy-Hunt syndrome (herpes zoster: look for vesicle around external auditory meatus).

c- Extracranial

i- Parotid tumor

ii- Trauma

d- General conditions:

i- Common

- Idiopathic Bells palsy
- Diabetes mellitus
- Hypertension

ii- Rare

- Sarcoidosis
- Connective tissue diseases
- Infectious mononucleosis
- Melkersson's syndrome (facial edema, fissured tongue)
- Dystrophia myotonica

4- Bilateral emotional weakness. There is a mask like face, complete lack of the normal play of expression, and diminished eye blinking, yet when blinking occurs it is normal and there is transformation when the patient smiles. It is commonly caused by Parkinsonism.

5- Bilateral upper motor neuron palsy. The masking is not so marked, blinking is little affected, but the mouth can not be moved on command, yet often appears to move quite well during ordinary conversation. Jaw jerk is exaggerated.

Common causes (4Ms)

i- Multiple cerebral infarctions

ii- Multiple sclerosis

iii- Motor neuron disease

iv- Motor cycle accident (trauma)

- 6- Bilateral lower motor palsy: there is flattening of all normal folds. The corners of the mouth sag. The lower part of the face is flattened and appears expressionless. All attempts at voluntary movement fail, and the white of the eyes are seen when the patient attempt to close them or to blink. Look at the pictures at page 94.

Causes

1-Benign

Bilateral Bells palsy, Guillain Barre Syndrome, multiple cranial neuropathy, brainstem encephalitis, Miller-Fisher syndrome, idiopathic intracranial Hypertension

2-Tumor

Meningeal leukemia, prepontine tumors and pontine tumors

3-Infections

Syphilis, leprosy, AIDS, fungal and tuberculosis

4-Others

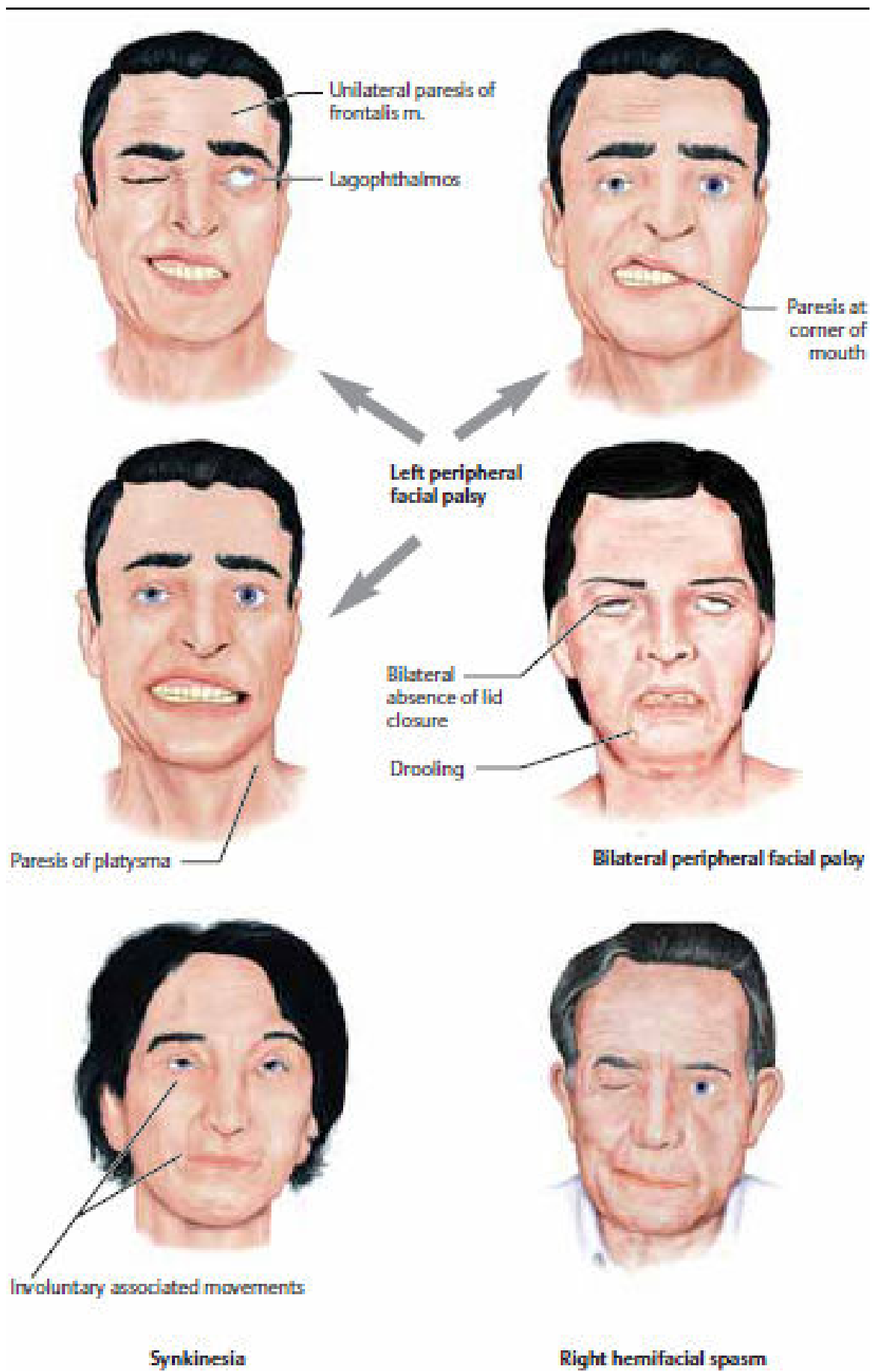
Diabetes mellitus, sarcoidosis, head injury, pontine hemorrhage, Mobius syndrome and systemic lupus erythematosus.

Loss of taste

Ageusia or loss of taste occurs with lesions of the peripheral pathways or with centrally placed pontine lesions which may involve the gustatory lemmes. Loss of taste may result from lesions in any part of the peripheral and central course of the taste fibers. Bilateral loss of taste usually is loss of flavors, due to anosmia, the primary taste remaining intact when tested. Occasionally, true bilateral loss occurs in demyelinating or vascular lesions of the brainstem involving the nucleus of solitary tract but this is usually temporary. Table 12 defines the important sites of lesions affecting the facial nerve.

Table 12. Localization of lesions affecting cranial nerve VII

Site	Examples	Clinical features
Cortex Supranuclear	Cerebral infarction, Hemorrhage, tumor	Contralateral facial and body weakness of upper motor neuron type.
Pons Nuclear	Infarction, demyelination, hemorrhage, tumor	All parts of ipsilateral face are weak; often VI nerve is affected with or without contralateral hemiparesis.
Cerebellopontine angle	Acoustic neuroma, meningioma	All parts of the face are affected, associated with deafness and tinnitus with or without trigeminal nerve being affected.
Facial canal (petrous bone)	Bell's palsy, mastoiditis, herpes zoster	All parts of the face are affected with or without loss of taste, salivation and Lacrimation, hyperacusis if stapedius weak.
Parotid gland	Tumor, sarcoidosis	Selective weakness of parts of the face due to branch involvement.
Neuromuscular junction	Myasthenia gravis	Associated ptosis and external ophthalmoplegia, dysarthria with or without limb weakness.
Muscle	Muscular dystrophy	Limb muscles are also weak



3-6: The Eighth Cranial Nerve (The Auditory nerve)

Functions:

- a- The cochlear nerve: Hearing. See Figure (7).
- b- The vestibular nerve: Balance and sensation of the bodily displacement (head position and head movement). See Figure (8)

Purposes of the tests:

- 1- To determine whether any deafness is unilateral or bilateral, conductive or sensorineural.
- 2- To determine whether disturbance of vestibular functions (mainly vertigo) originate in the labyrinth, the vestibular nerve or the brainstem.

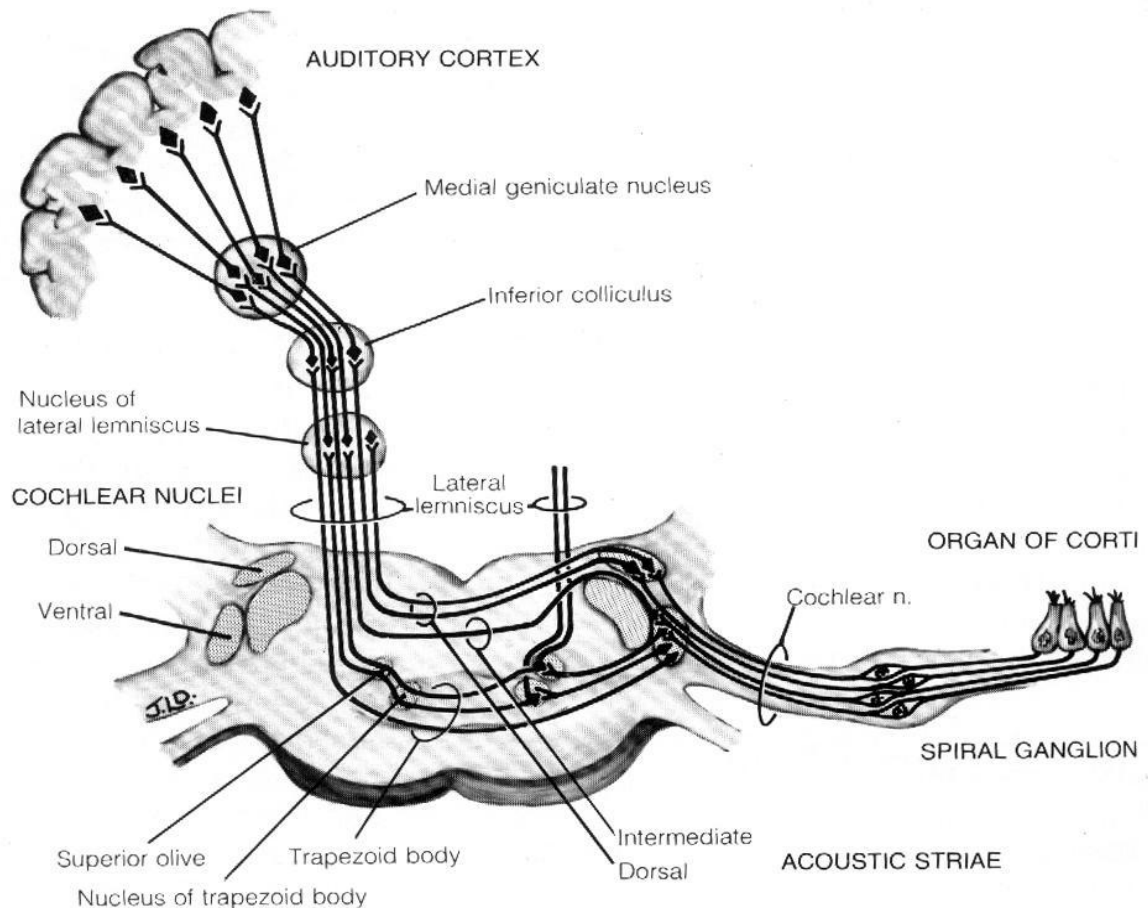


Figure 7: Schematic diagram of the auditory pathways

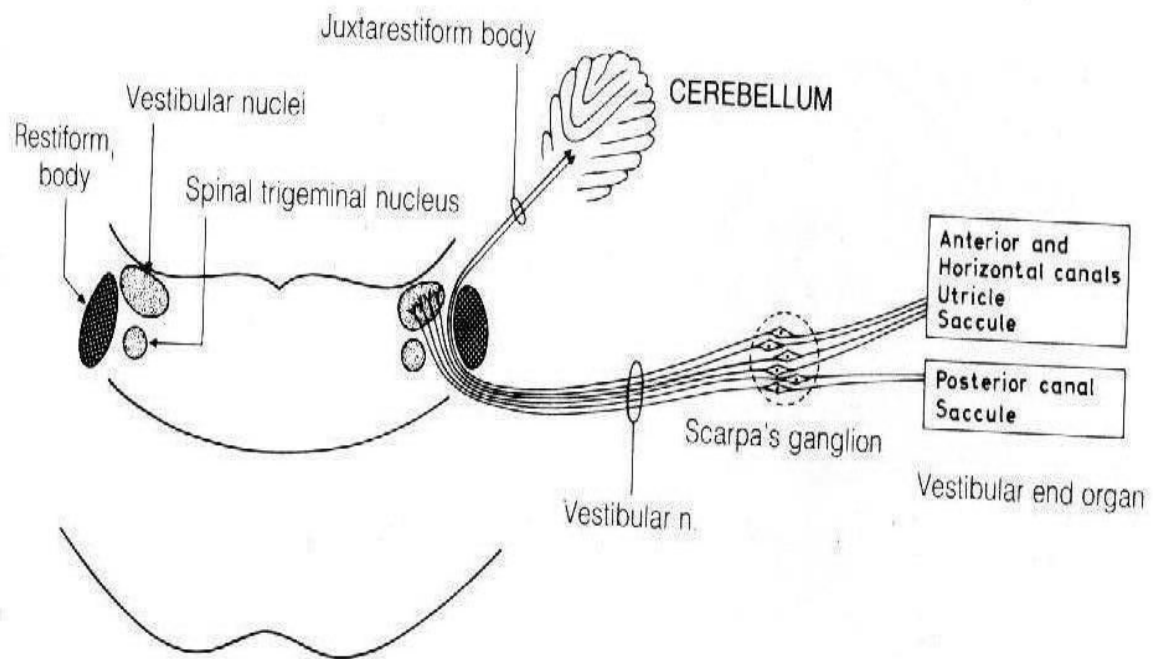


Figure 8: Schematic diagram of the origin and termination of the vestibular fibers.

Methods of examination

Hearing

- 1- A simple bedside test of hearing is carried out by rubbing of fingers near both external meatus and asking the patient to compare these sounds. Ask him whether he hears these sounds equally (normal) or there is impairment of hearing in one side or he can not hear it at all.
- 2- If deafness is present, the auroscope must be used to exclude the presence of wax or any disease of the middle ear and drum.
- 3- Next, it must be determined whether the observed hearing loss is due to sensorineural process (i.e. a lesion central to the oval window), or a conductive cause (i.e. the lesion is located between the environment and organ of Corti), in bedside qualitative assessment of hearing loss a tuning fork (512 or 265 Hz because lower frequencies introduce a component of vibration into the testing) is used to distinguish between these 2 types of hearing loss.
- 4- There are three main tuning fork tests for evaluation of hearing loss.
 - a- Rinne test: The stem of the vibrating tuning fork is applied to the mastoid bone. When the patient is no longer hears the vibrations, the instrument is

placed next to the ear, 1 inch from the external auditory meatus. In normal people, because air conduction is better than bone conduction, the vibrations are perceived in the ear after they are no longer perceived at the mastoid. With conductive deafness, bone conduction is better than air conduction, and therefore the tuning fork can not be heard when it is placed next to the ear. With sensory-neural deafness, air and bone conductions are impaired to a similar extent, and air conduction remain greater than bone conduction.

- b- Weber test: A vibrating tuning fork is placed over the midline of the skull or forehead. Normally, the vibration will be perceived equally in both ears (no lateralization) because bone conduction is equaled bilateral. In conductive deafness, the vibrations are louder in the deaf ear. In sensorineural deafness, the sound is louder in the normal ear.
- c- Schwabach test: As in Rinne test, the fork is held against mastoid process until the patient is unable to perceive any sound. The examiner then places the tuning fork over his, own mastoid bone and thus compares his own bone conduction to that of the patient. If the examiner hears the vibration after the patient no longer hears it, a sensorineural hearing loss is suspected.

5-Later, more formal quantitative audiologic tests are performed e.g. are pure tone audiometry, speech discrimination audiometry, loudness recruitment, tone decay, Bekesy audiometry, short increment sensitivity index (SiSi), the acoustic-stapedial reflex and computerized brain stem auditory evoked potential (BAEP). These special tests are helpful in distinguishing cochlear from retrocochlear (nerve) lesion. Although an absolute distinction can not be made on the bases of any one test, results of the tests when taken together make it possible to predict the site of the lesion with considerable accuracy. These tests usually carried out by an otologist or audiologist. Of these tests, threshold tone decay and auditory recruitment are the most helpful in distinguishing sensory-neural hearing loss of cochlear origin from that from primary nerve deafness.

Vertigo and vestibular functions

The physical examination in vertiginous patient should include a complete otologic and audiology evaluation and a complete neurological evaluation. This examination should stress on the followings:

- 1- Blood pressure evaluation in both arms (including tests for postural changes), with search for bruit and cardiac arrhythmias.
- 2- Gait & stance: Rombergism, deviation of out stretched hands.
- 3- A detailed cranial nerve examination, including tuning fork evaluation of hearing, nystagmus, vision, ocular motility etc.
- 4- Cerebellar testing, especially evaluation for nystagmus, gait, and ataxia.
- 5- Provocative tests designed to induce symptoms (vertigo, nystagmus). They include postural changes, head turning, Nylen-Barany test and caloric testing.
- 6-Systemic examination which includes: cardiac, haematological, endocrine and metabolic diseases

Causes of conductive deafness

They include all diseases of the external meatus, middle ear, and Eustachian tube, none of which come directly within the sphere of neurological disease. Detection of middle ear infection is off course of paramount importance in suspected intracranial infection, and certain middle ear tumors extend intracranially (e.g. tumors of glomus jugulare).

Common causes of perception deafness and their localization

- a- At cochlear level: Menier's disease, advanced otosclerosis, deafness due to drugs, internal auditory artery occlusions, prolonged exposure to loud noise.
- b- In the nerve trunk: Old age, post-inflammatory lesions (e.g. syphilis, bacterial infection), toxic lesions, drugs (e.g. streptomycin, neomycin), meningitis, cerebellopontine angle tumor, trauma (e.g. basal skull fractures).
- c- In the brainstem: Bilateral severe pontine vascular lesions, severe demyelinating lesions, occasionally tumors.

- d- Cerebral lesions: Destructive bilateral lesion of temporal auditory cortex or unilateral dominant posterior temporal lesion may cause pure word deafness. Irritative lesions of the temporal cortex may result in tinnitus or temporal lobe epilepsy with acoustic or vertiginous auras.

Localization of lesion causing sensorineural deafness

- 1- At the cortical level: Pure word deafness, temporal lobe epilepsy is associated with acoustic or vertiginous auras, and other features of temporal lobe dysfunction.
- 2- At brainstem level: Gross and profound neurological disability is present. Associated brainstem findings dominate the clinical picture.
- 3- At the cerebellopontine angle: The V and VII cranial nerves are also involved.
- 4- At the level of nerve or cochlea: Difficult to separate clinically, but certain audiological tests may be of great help. The most important is tone decay and auditory loudness recruitment.

Localization of lesions causing vertigo

The localization of lesions causing vertigo may be approached by dividing these etiologies into:

- 1- Peripheral: Labyrinth or vestibular nerve.
- 2- Central: Vestibular nuclei or their connections.
- 3- Systemic causes: including cardiac, endocrine, hematological and metabolic diseases.

Features of peripheral vertigo

- 1-Usually of short duration
- 2-Vertigo is severe, and often paroxysmal
- 3-Auditory dysfunction (Tinnitus and deafness) is usually present.
- 4-Nystagmus is often seen, it is characteristically unidirectional (fast phase is away from the lesion) and horizontal-rotatory (never vertical or exclusively rotatory). This nystagmus is inhibited by visual fixation.

5-Past-pointing, subjective environmental rotations, deviation of outstretched hand and Romberg fall are toward the slow phase of the nystagmus (toward the side of the lesion).

6-Provocative tests

a: Nylon barany-(Briskly tilting the patient's head backward and turning it 45 degree to one side) allows differentiation between peripheral and central origin for positional vertigo as follow:

With peripheral lesion: Sever vertigo and nystagmus appears several seconds after the head position is changed (latency of response).This nystagmus is usually rotatory, with the fast phase toward the diseased ear. The vertigo and nystagmus then fatigue and abate within 10 seconds after appearance(fatigability),and when the patient is rapidly brought back to sitting position ,vertigo occurs and nysatgmus may occur in the opposite direction (rebound) .With repetition of the maneuver, the symptoms and nystagmus become progressively less sever(habituatation)and the reproducibility of the abnormality is inconsistent

With central lesion: vertigo and nystagmus begin immediately on changing head position (no latency), and the response don't fatigue or demonstrate habituation with repetitive trials. The duration of vertigo is usually no longer than 60 seconds, and the vertigo induced is relatively mild. The nystagmus is more often direction –changing than fixed and may be produced by more than one head position.

B-Caloric testing

1-Canal paresis—mainly peripheral causes

2-Direction preponderance---central causes

Causes of peripheral vertigo

1-Positional vertigo: usually of peripheral type (rarely secondary to central lesions)

2- Meniere's disease.

3-Peripheral vestibulopathy, which includes: vestibular neuronitis and acute labyrinthitis.

4-Head injury, trauma

5-otosclerosis

6- Drugs e.g. are: Aspirin, alcohol, quinine, quinidine, aminoglycoside, diuretics and sedatives.

Features of central vertigo

- Central vestibular syndrome is usually prolonged (permanent or chronic) rather than of short duration.
- Intrinsic brainstem and cerebellar signs are usually present.
- Auditory symptoms are less frequent.
- Vertigo is usually less severe, ill defined and continuous in nature.
- Nystagmus is bi-directional unidirectional may be exclusively horizontal, rotatory or vertical and is not altered by visual fixation.
- The direction of subjective environmental rotation and Romberg fall are variable and are not significantly altered by changes in head position.
- **Provocation** tests-----discussed previously.

Causes of central vertigo

1-Vascular causes -----e.g. are TIA of vertebrobasilar artery, labyrinthine stroke, Wallenberg's syndrome, MS and migraine

2-Cerebello-pontine angle tumors.

3-Vestibular epilepsy.

4-Wernicke's encephalopathy.

5-Posterior fossa tumors.

Systemic causes of vertigo

They cause either peripheral or central type of vertigo. The important causes are:

1-Cardiac e.g. are: arrhythmias, aortic stenosis, congestive heart failure, cardiomyopathy, carotid sinus hypersensitivity, and other valvular lesions.

2-Haematological disorders like polycythemia, anaemia, and hyperviscosity syndrome.

3-Hypoglycaemia

4-Hypothyroidism.

5-Hyperventilation syndrome.

6-Multiple sensory deficits. Dizziness in older patients (especially elderly diabetic) may result from combination of sensory deficits including, visual impairment, neuropathy, vestibular dysfunction, and cervical spondylosis, specially prominent during ambulation.

2-7: The Ninth & Tenth Cranial Nerves

(The glossopharyngeal and vagus nerves)

Functions

The followings are the most important and accessible in neurological examination:

1. Motor functions:

- a) Motor supply to the palate, pharynx.
- b) Motor supply to the larynx (vocal cords), purely by the vagus.

2. sensory functions:

- a) Common sensation: from the pharynx, tonsils, soft palate and posterior third of the tongue.
- b) Taste sensation: from the posterior third of the tongue (purely by IX cranial nerve)

3. reflex functions:

Gag reflex and the palatal reflex.

Figures 9 and 10 show the areas supplied by these nerves

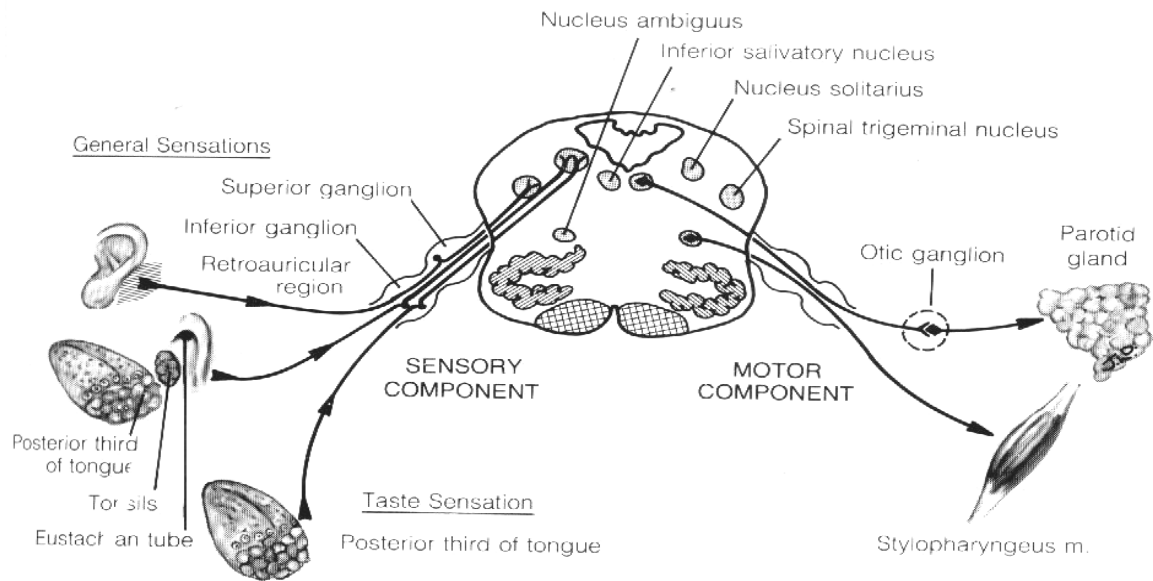


Figure 9: Schematic diagram of the component of the glossopharyngeal nerve and the structure the supply

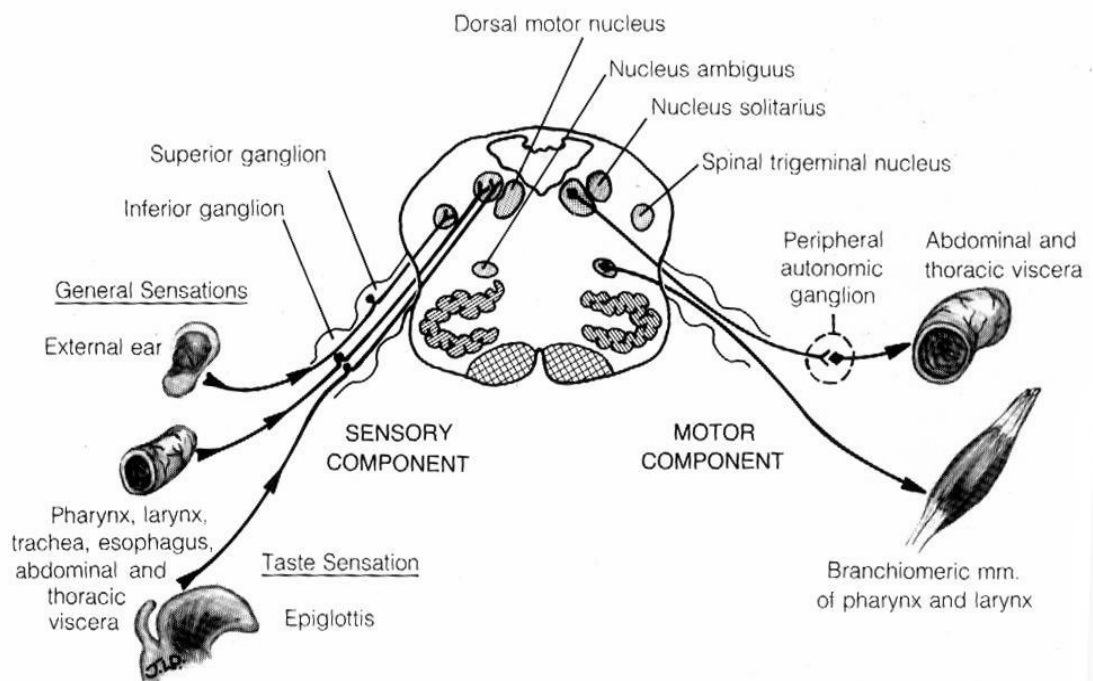


Figure 10: Schematic diagram of the components of the vagus nerve and the areas they supply

Purposes of the tests

To detect and analyze the following symptoms and signs that may result from lesions of these nerves:

1. Dysphagia.
2. Dysarthria.
3. Regurgitation of fluid from the nose.
4. Palatal movement's abnormalities.
5. Sensory functions' changes.
6. Reflexes functions' changes.

Methods of examination

1. Speech assessment.

- a. Listen to the clarity of patient's enunciation during history taking.
- b. Ask the patient to repeat certain phrases, start by simple phrases and then give the patient more complex phrases gradually, e.g. Diwania, Nasiria. British constitution and listen carefully for any slurring of words (cerebellar disorders).
- c. Ask the patient to count successively up to 30 or above, to test muscle fatigue (myasthenia gravis).

The followings are the important parameters that must be carefully noticed during speech examination:

- i. Rhythm of the words (jerky, explosive or monotonous).
- ii. Intensity of the speech (too loud, or too soft).
- iii. Pitch and quality of the speech (nasal tone, hot potato, hoarse voice, bovine).
- iv. Smoothness of the speech (slurred, harsh, fast, slow, poorly coordinated with breathing).
- v. Disturbance is variable or constant.

2. Dysphagia and regurgitation of fluid from the nose.

Give the patient a glass of water and ask him to drink, observe whether he drinks smoothly or he drinks by sips, also notice any regurgitation of fluid from the nose or cough after drinking water.

3. Motor function (palatal movement)

Ask the patient to open his mouth, a few moment wait, allowing the tongue to rest in the floor of the mouth. Then ask the patient to say "Ah", normally the palate should moves symmetrically upward and backward, the uvula remaining in the midline, and the two sides of the pharynx should contract symmetrically.

4. Sensory functions

Sensation of pain and touch are tested on the soft palate, posterior third of the tongue, tonsil region and the pharyngeal wall. This is easily achieved by a wooden tongue depressor that is made pointed for pain sensation on each side. Touch sensation can be examined by a throat swab with the cotton wool safely attached to it.

5. Reflex functions

- a. The gag reflex: This reflex can be tested by stimulating the posterior pharyngeal wall, tonsillar area, or the base of the tongue. The response is tongue retraction associated with elevation and constriction of the pharyngeal musculature.
- b. Palatal reflex: this reflex consists of elevation of the soft palate and ipsilateral deviation of the uvula with stimulation of the soft palate.

Results of examination

- **Dysarthria:** It means defects of articulation of speech. There are five main types:

1. Flaccid dysarthria:

This is due to weakness or paralysis of the articulator muscles, the result of disease of the motor nuclei of the medulla and lower pons or their peripheral connections. Speech as whole may be well preserved, but individual words

and sounds cause difficulty. The degree of muscular weakness governing the particular variety of defect produced:

- i. Facial paralysis: Causes difficulty with labials such as (B, P, M, W).
- ii. Tongue paralysis: affect large number of sounds (I, D, U, S, T, X, Z) and speech is profoundly distorted.
- iii. Palatal paralysis: produce nasal speech, B and D become M, N and G become (rh) and K sound like (ng). The head position alters the degree of defect, the patient's speech being worse when the head is bent forwards.
- iv. Myasthenia gravis: the voice may be normal at the beginning of the sentence, but abnormalities develop as the sentence progresses. Dysarthria may be of any type, but particularly of palatal weakness and including hoarseness. This is usually demonstrated by asking the patient to count up to 30.

2. Spastic dysarthria

This is caused by bilateral upper motor neuron disease. The speech is slurred; the patient cannot open his mouth or protrude his tongue freely. He talks as if there is a hot potato in his mouth, hence a hot potato speech. The impression gained that he talks from the back of his throat.

3. Ataxic dysarthria:

This is caused by cerebellar diseases. There is in coordination of muscle of speech. Speech is irregular, slurred and drunken. The rhythm is jerky, sometimes explosive, staccato or scanning. Think of intoxicated person's speech.

4. Rigid dysarthria:

This is due to extra-pyramidal lesions, producing rigidity of the face or the tongue muscle, without wasting and without exaggeration of reflexes. Speech is monotonous, sentences start and stop suddenly. Excursion of the tongue and lips are greatly reduced. The latter words in long sentence may come out in a rush.

5. Dysarthria in dysphasic patient

Some degree of dysarthria may accompany expressive dysphasia, and also found in lesions producing severe apraxia of muscles of articulation.

Dysphagia

It occurs immediately after swallowing is attempted. Tracheal aspiration occurs causing cough and laryngismus with an increasing risk of aspiration pneumonia. Management of this distressing condition requires nasogastric feeding. It is usually due to pharyngeal muscle weakness (hence pharyngeal dysphagia) that results from vagus nerve lesions at different levels. The followings are the characteristic features at each level:

1. Unilateral upper motor lesions: It is usually mild and transient due to bilateral supranuclear control.
2. Bilateral upper motor neuron lesion: Dysphagia is usually prominent symptom and it is usually more marked for solids.
3. Unilateral lower motor neuron lesion: Dysphagia is usually profound and disabling but it is usually improves with passing of time.
4. Bilateral lower motor neuron lesion: Dysphagia is usually more profound and severe; it is usually more pronounced for liquids and associated with severe regurgitation of fluid from the nose.

Regurgitation of fluid from the nose

This is a common symptom in total paralysis of the soft palate, owing to defective elevation of it during swallowing. In unilateral paralysis this symptom is usually not observed.

Motor function (Vagus nerve)

1. Unilateral upper motor neuron palsy: Since the bulbar muscles on each side are innervated by both motor cortices, there may be no impairment of speech or swallowing from unilateral cortico-bulbar palsy. On examination, palatal movement is impaired contra laterally, the uvula is deviated to the normal side, gag reflex and sensation is normal. Causes: stroke, tumor, trauma.

2. unilateral lower motor neuron palsy

- Dysphagia and dysarthria may occur.
- On examination: the ipsilateral palate fails to elevate, and the uvula is retracted to the non-paralyzed side. Gag reflex is absent ipsilaterally which ever side is stimulated. Stimulation of the normal side will cause the palate to pull toward that side. The ipsilateral vocal cord will assume the cadaveric position (midway between adduction and abduction), and although voluntary coughing may be impaired, there is little dyspnea.
- Causes: medullary infarction, syringobulbia, posterior fossa tumors, vascular anomalies, tumors or glandular enlargement at or below the jugular foramen, trauma.

3. bilateral upper motor neuron lesion (pseudobulbar palsy)

- The patient has prominent dysphagia (mainly for solids), dysarthria (spastic type), dysphonia and regurgitation of fluid from the nose.
- On examination: No movement of the palate and pharynx. The palatal and gag reflexes retained or increased. Uvula is in the midline. Jaw jerk and other facial reflexes are exaggerated. The tongue is small and spastic, emotional control is impaired (spasmodic laughing or crying). Sometimes the breathing become periodic (cheyne-stokes breathing)
- Common causes (**4 Ms**)
 - a. Multiple cerebral infarctions.
 - b. Multiple sclerosis.
 - c. Motor neuron disease.
 - d. Motor cycle accident (trauma).

4. Bilateral lower motor neuron palsy (bulbar palsy).

- The patient has profound dysphagia, more pronounced for liquids; speech has nasal quality due to escape of air from oral to the nasal cavity. Patients also have severe regurgitation of fluid from the nose.

- On examination: the palate droops bilaterally with no palatal movement on phonation. Gag reflex and sensation of the posterior pharynx are absent. Coughing is poor or not possible, and respiration is severely embarrassed. Vocal cords assume bilaterally cadaveric positions.
- Causes: myasthenia gravis, poliomyelitis, diphtheria, toxins, Guillain-Barre syndrome, progressive bulbar palsy.

Sensory function

The integrity of taste sensation is lost ipsilaterally with IX cranial nerve lesion sensation of pain and soft touch may be ipsilaterally lost with glossopharyngeal lesion.

Reflex function

Unilateral loss of the gag reflex may be due to loss of sensation, of motor power or both. There are 4 possibilities of lost gag, they are:

1. Unilateral glossopharyngeal lesion: No gag reflex ipsilaterally, but stimulation of normal side will produce symmetrical reflex i.e. both side of palate elevate equally.
2. Unilateral combined vagus and glossopharyngeal nerves lesion: In this condition stimulation of the normal side will cause the palate to be pulled towards that side.
3. Bilateral glossopharyngeal and vagus nerves lesion: bilateral loss of gag reflex, bilateral anesthesia of the posterior pharynx. This indicates severe medullary lesion.
4. non-organic causes: Bilateral loss of gag jerk, but the palate move normally and symmetrically, when you ask the patient to say "AH"

For localization of the lesions, affecting ninth and tenth cranial nerves, see Tables (13) & (14).

Table 13. Localization of lesions affecting the glossopharyngeal nerve

Site	Causes	Clinical features
Supranuclear	Stroke, cerebral tumor, demyelination, motor neuron disease	Unilateral lesion do not cause persisting deficit. Bilateral lesions cause pseudobulbar palsy.
Nuclear	Infarction, syringobulbia, tumor, demyelination	Usually associated with vagus nerve lesion and other brain stem signs.
Jugular foramen	Glomus tumor, basal skull fractures, metastasis	Involve IX, X, XI cranial nerves
Lesions within the retropharyngeal and the retro parotid spaces	Naso-pharyngeal carcinoma, abscess, adenopathy, aneurysm, trauma or surgical procedures e.g. carotid endarterectomy	Resulting syndrome include: 1. Collet-Sicard syndrome (affecting cranial nerves IX, X, XI, and XII). 2. Villaret syndrome (affecting cranial nerves IX, X, XI, XII, and the sympathetic chain)

Table 14. Localization of lesions affecting the vagus nerve

Site	Causes	Clinical features
Supranuclear (cortex & pyramidal tract)	Stroke, cerebral tumor, demyelination, motor neuron disease	Unilateral lesions do not cause persisting deficit. Bilateral lesions cause pseudobulbar palsy.
Nuclear lesion (brain stem)	Infarction, syringobulbia, tumor, demyelination	Ipsilateral X lesion of lower motor neuron type plus brain stem signs.
Lesion within the posterior fossa (from it's emergence to it's exit from the jugular foramen)	Glomus jugulare tumors, metastatic tumors, infections, trauma.	Lesions at this site usually involve cranial nerves IX, X, XI, XII at variable combination usually ipsilateral and of lower motor neuron type.
Lesions affecting the trunk of the vagus nerve	Trauma, surgery, tumor, aneurysm, enlarged lymph nodes	Complete vocal cord paralysis associated with unilateral laryngeal anesthesia, IX, & X of lower motor neuron lesion type.
Superior laryngeal nerve	Trauma, surgery, tumor	Mild hoarseness. This nerve is purely sensory a part from it's supply to the cricothyroid muscle.
Unilateral recurrent laryngeal nerve	Aneurysm, lymphoma, mediastinal tumor, operative damage e.g. thyroidectomy.	Transient hoarseness of voice, vocal cord lies near the midline ipsilaterally.
Bilateral recurrent laryngeal nerve	Thyroidectomy, trauma, enlarged cervical glands.	Dyspnea, stridor, bilateral abduction paralysis lead to severe approximation of vocal cords, which often necessitates tracheostomy.

2- 9: The Eleventh Cranial Nerve ((The Accessory nerve)

Functions

To give motor power to the upper part of the trapezii and to the sternomastoids and so to influence the posture and movements of the head and shoulder girdles (Figure 11).

Purposes of the tests

1. To detect whether the weakness (\pm) wasting is unilateral or bilateral.
2. Localization of lesions affecting the nerve.

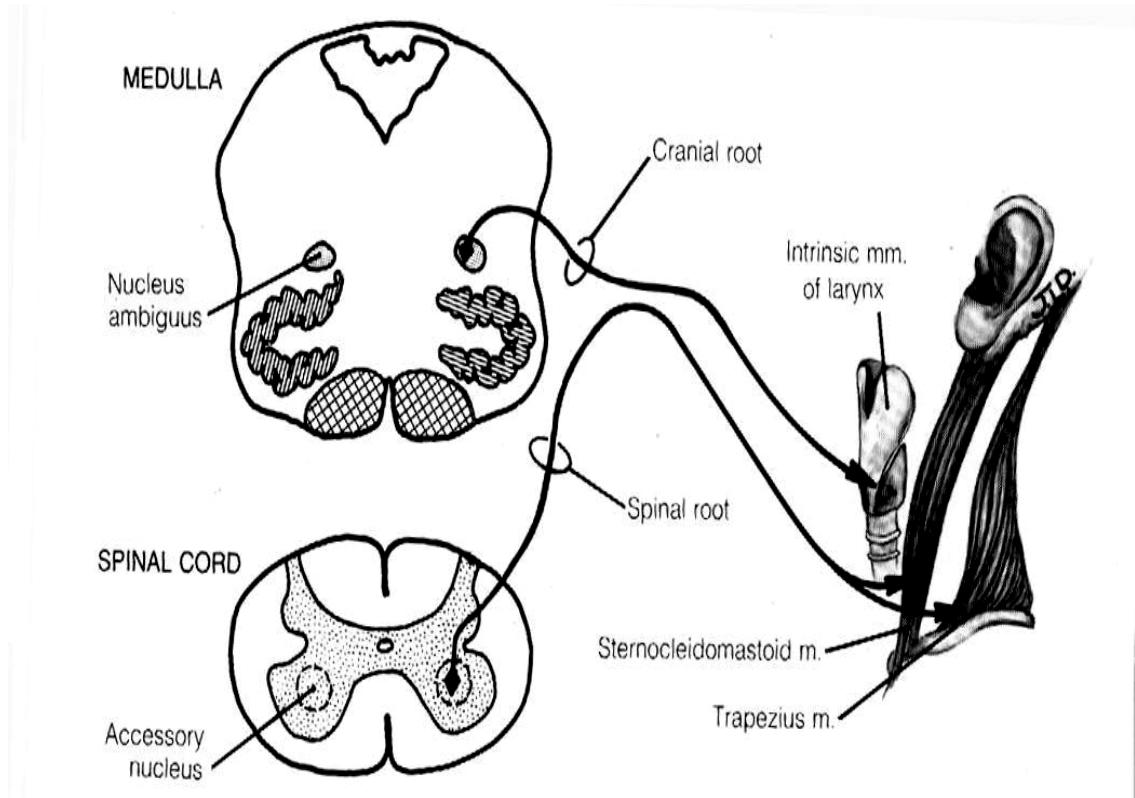


Figure 11: Schematic diagram illustrating the neurons of origin of the accessory nerve and muscle supplied by the nerve

Methods of examination

1. inspection: look for:
 - a. Wasting, atrophy.
 - b. Fasciculation.
 - c. Abnormal head posture (it fall forwards in severe trapizius weakness, but it falls backwards in severe sternmastoids weakness). Also look to the position of the scapulae.
2. Palpation: Palpate the bulk of these muscles and compare the two sides. Wasting is usually precedes overt weakness, and sometime there is severe wasting and the power is still normal because head turning and shoulder elevations are not achieved purely by the accessory nerve.

3. power

- a. Sternomastoids: place one hand against the right side of patient's face and ask him to turn (not bend) his head against it. The left sternomastoid will stand out clearly. Repeat this maneuver in the opposite direction and compare the two sides for bulk and strength. Then put your hand on his forehead and ask him to bend his head forwards. Both sternomastoids will stand together and are easily compared. Now ask the patient to sit up. Normally the head leaves the pillow first and the movement is easy.
- b. Trapezius: Ask the patient to raise his shoulders toward his ears. Now try to depress the shoulder forcibly.

Results of examination

1. Unilateral sternomastoid paralysis

- Unilateral wasting, fasciculation (in the lower motor neuron lesion). The patient will fail to turn his head against resistance to the opposite side.
- Causes: Trauma in the neck or base of the skull, viral disease including poliomyelitis, tumors at jugular foramen level, bony anomalies of the base of the skull, syringomyelia.

2. Unilateral trapezius paralysis

- The shoulder droops on the affected side, scapula displaced downwards and laterally, shrugging of the shoulder may be weaker though not absent. Wasting and fasciculation, if nuclear or infranuclear lesion.
- Causes: the same as above.

3. Bilateral sternomastoid paralysis

- Wasting and fasciculation (if due to lower motor neuron lesion).
- Head posture: it falls backwards due to weakness of neck flexion.

- Power: the patient fails to bend his head forward against resistance and when he sit up, the head seems to be left on the pillow, and then is raised with difficulty.
- Cause: dystrophia myotonica, motor neuron disease, polyneuritis.

4. Bilateral trapizius muscle paralysis

- Bilateral wasting and fasciculation in lower motor neuron lesions.
- Head falls forwards when the patient attempt to stand erect.
- The patient cannot bend his head backwards against resistance.
- Causes: Motor neuron disease, polyneuritis, poliomyelitis.

Localization of lesions.

The common causes affecting the accessory nerve, their sites and their clinical features are listed in table (15)

Table 15. Localization of lesions affecting cranial nerve XI

Site	Causes	Clinical features
Supranuclear lesion	Stroke, cerebral tumor, demyelination (DS), motor neuron disease.	Slowness and weakness of the contralateral trapizius but ipsilateral sternomastoids.
Nuclear lesion	Motor neuron disease, syringobulbia, tumor, Ds	Bulbar weakness plus wasting, weakness and fasciculation of the trapizius and sternomastoid plus brainstem signs.
Lesions within the skull and foramen magnum	Extramedullary neoplasm, trauma, meningitis.	Involvement of the neighboring cranial nerves IX, X, XI, XII plus signs of spinal cord compression.
Jugular foramen	Mentioned	Discussed with cranial nerve IX.
Retroparotid and retropharyngeal spaces	Mentioned	Involve cranial nerves IX, X, XI, XII and the nearby sympathetic chain in variable combination.
Within the neck	Trauma, adenopathy, tumor.	Ipsilateral trapizius and sternomastoid. No affection of other cranial nerves.
In the posterior cervical triangle	Same cause	Only the trapizius muscle will be involved.

2-10: The Twelfth Cranial Nerve (The Hypoglossal Nerve)

Functions

It controls all movement of the tongue and certain movement of the hyoid bone and larynx during and after deglutition. It is the motor supply to intrinsic and most of the extrinsic muscles of the tongue.

Purposes of examination

1. To detect whether lesion of the hypoglossal nerve is unilateral or bilateral and to know whether it is of upper or lower motor neuron type.
2. Localization of the lesions affecting the cranial nerve.

Methods of examination

1. ask the patient to open his mouth and look for the following signs while the tongue is inside the mouth (i.e. at rest):
 - a. Atrophy.
 - b. Tremor.
 - c. Fasciculation.
2. then ask the patient to put his tongue out and look for:
 - a. Any deviation from the midline.
 - b. Any abnormal movement.
 - c. Any difficulty in performing this movement.

Results of examination

1. unilateral upper motor neuron lesion (UMNL): Because the supranuclear control of the genioglossus originates mainly from the contra lateral cortex, a lesion of the corticobulbar fibers above their decussation may result in:
 - a. Weakness of the contra lateral half of the tongue.
 - b. The tongue deviates toward the side of hemiplegia.
 - c. No atrophy or fasciculation (normal looking), symmetrical tongue.
2. unilateral lower motor neuron lesions (ULMNL): It result in:

- a. Paresis, atrophy, and fasciculation of the ipsilateral half of the tongue.
 - b. The tongue deviates to the side of the lesion.
 - c. Dysphagia and dysarthria are minimal but difficulty in manipulating food in the mouth is evident.
3. Bilateral upper motor neuron lesion (pseudobulbar palsy): it result in:
- a. Small and spastic tongue
 - b. No atrophy or signs of denervation.
 - c. Protrusion and lateral movement of the tongue movements are slow, restricted, and irregular owing to poor supranuclear control (spastic tongue)
 - d. Spastic dysarthria and other features of pseudobulbar palsy are evident.
4. Bilateral lower motor neuron lesions: it results in bilateral:
- a. Weakness, atrophy, fibrillation, and fasciculation of the tongue.
 - b. The tongue can not be protruded voluntarily.
 - c. Marked difficulty in articulation, especially with pronunciation of d and t phonemes.
 - d. Dysphagia is prominent.
 - e. Breathing difficulty may occur when the flaccid tongue falls backward to obstruct the pharynx.

Localization of lesions

Causes affecting the nerve, their sites, and their clinical features are listed in Table (16)

Table 16. Localization of lesions affecting cranial nerve XII

Site	Causes	Clinical features
Supranuclear lesion	Stroke, multiple sclerosis (MS), tumor.	Unilateral: contralateral weakness of half of the tongue. Bilateral: pseudobulbar palsy.
Nuclear lesion	MS, syringomyelia, motor neuron disease (MND), poliomyelitis.	Ipsilateral hypoglossal nerve lesion of LMNL type, or Bilateral hypoglossal nerve lesion of LMNL due to close proximity of the 2 hypoglossal nuclei.
Intramedullary lesion as general	Tumors, multiple sclerosis, syringobulbia, stroke.	Ipsilateral XII nerve lesion of LMNL plus contralateral pyramidal weakness, plus contralateral loss of vibration and position sensation (medial lemniscus) plus other neighboring medullary structures.
Medial medullary syndrome	Anterior spinal artery occlusions.	The same as above
Peripheral lesion (at the base of the skull)	Basilar skull fractures, trauma, tumors.	XII nerve lesion of LMN type plus variable combination of IX, X, and XI nerves lesion, when all the above cranial nerves are damaged a Collet-Sicard syndrome results.
Peripheral lesion at retro pharyngeal, retrostyloid, or in the neck.	Tumor, trauma, metastasis, surgery, chronic infection.	Ipsilateral XII lesion of LMN type plus variable combination of IX, X, & XI plus Horner syndrome if in the neck. It may include Collet-Sicard, Tapia, villaret, Jackson and Garcin.
peripheral lesion in the neck or distal	Carotid aneurysms, local infection, surgical or accidental trauma, tumours of retroparotid or retro pharyngeal spaces, neck, salivary glands and base of the tongue	Isolated ipsilateral lower motor neuron type of the twelve cranial nerve

CHAPTER THREE

NEUROLOGICAL EXAMINATION OF THE UPPER AND LOWER LIMBS

This part includes examination of the motor system, sensory systems and the gait according to the following steps:

3-1 - Motor system examination:

3-1-1. Inspection

3-1-2. Tone

3-1-3. Power

3-1-4. Reflexes

3-1-5. Co-ordination

3-2 Sensory system examination:

3-2-1-Principle of sensory system examination

3-2-2. Methods of sensory system examination

3-2-3. Patterns of sensory loss

3-3- Gait examination

3-1 -Motor system examination:

3-1-1-Inspection:

Purpose of inspection: The important points of interest in most neurological examination are to detect, analyze and categorize the following important signs:

1. Muscle wasting.
2. Fasciculation.
3. Abnormal postures.
4. Abnormal movements.

1- Muscle wasting:

Methods of examination

- 1) Examine the patient lying, sitting and later standing, placing the limbs in symmetrical positions.
- 2) Inspect the muscles of the shoulder girdles, upper arm, forearms, hands, hip girdles, thighs and calves.

- 3) If wasting is observed, define which muscles are affected and compare it with their fellows on the other side.
- 4) If there is doubt about muscle wasting, this must be confirmed by measurement procedures at clearly stated places e.g. 10 cm above or below the olecranon, 18 cm above the patella, and 10 cm below the tibial tuberosity.
- 5) Look for the acquired lesions of local structures that may explain wasting. This includes deformities of joints, bones, surgical operations, wounds, osteoarthritis, or rheumatoid arthritis and Dupuytren's contractures.

Types of muscle wasting:

1. Global (generalized) wasting: this is commonly seen in systemic diseases such as malignancy, thyrotoxicosis, tuberculosis, malabsorption ...etc. Wasting is also seen in very advanced stages of many neurological diseases. The commonest causes of neurological disorders that cause generalized wasting are myopathies and motor neuron disease.

2. Proximal muscle wasting: This pattern of wasting can be seen in many neurological disorders, usually in the early stages of the illness. The followings are the most common disorders:

- a. Muscular dystrophies: It must be realized that the end stage of all muscular dystrophies can be similar. It is the early signs that differentiate the types and so are invaluable in prognosis.
- b-Motor neuron disease: wasting and fasciculation may often be marked in the shoulder girdles when distal muscles appear normal.
- c-Syringomyelia: Often starting in the shoulder girdles.

D-Inflammatory lesions:

- i. Neuralgic amyotrophy: Wasting usually start in the shoulder girdle and it is usually but not invariably unilateral.
- ii. Old poliomyelitis: muscles having the same segmental supply are involved.
- iii. Myositis: Usually proximal wasting and tenderness.

E-Compression lesions

*.At C5, C6 level: Usually wasting involves the outer aspect of the arm.

*.Cauda equina lesions: usually causes wasting of the buttocks.

3. Distal muscle weakness: Nearly all the conditions mentioned already, if severe enough, will affect the peripheral muscle as well. In the early stages, however, certain diseases may be confined to the distal muscles.

a. The forearm and small muscles of the hands

i. Lower motor neuron lesion: Affecting principally the segmental distribution of C7, C8 and T1. This may occur at the following levels:

- Anterior horn cells (poliomyelitis, motor neuron disease, syringomyelia, cervical cord tumor).

- The anterior root (cervical spondylosis, cervical tumors).

- Brachial plexus (injuries, cervical rib, cervical glandular enlargement, superior pulmonary sulcus tumor).

- Traumatic lesions of the radial, median, and ulnar nerves.

ii. Carpal tunnel syndrome which causes wasting of the thenar eminence.

iii. Ulnar nerve pathology: If it is damaged at or just below the elbow, there will be wasting of most of the small muscles except opponens pollicis and abductor pollicis brevis. While injuries at the wrist or compression by a ganglion may spare the hypothenar eminence and sensation.

iv. Muscular lesions: It includes dystrophia myotonica, those due to aging process or rheumatoid arthritis.

v. Contralateral parietal lobe lesions: it occurs very occasionally.

b. The lower leg wasting

i. Peripheral neuropathy (polyneuritis).

ii. Extensive cauda equine lesion.

iii. Peroneal muscular atrophy.

iv. Poliomyelitis.

v. Peripheral nerve trauma, especially the common peroneal nerve e.g. by an inadequately padded plasters or by skin traction techniques.

vi. Wasting of the anterior muscles of the lower leg that follow "syndrome of the anterior tibial compartment"

c. **Peripheral wasting in both the lower and upper limbs.** Peripheral wasting in all of the 4 extremities is rare except in 2 conditions:

i. Peroneal muscular atrophy (Charcot-Marie-Tooth disease).

ii. Chronic polyneuritis.

Fasciculation

It is visible irregular flickering over the surface of the affected muscle caused by spontaneous contractions of individual motor units- suggests that weakness is due to a lower motor neuron lesion. They are most easily seen in large muscles as the deltoid or calves muscles and present at rest, stopping during voluntary movements but increased after it. It varies greatly in degree; it may be so coarse or sometimes very fine. They are of 2 types:

- a. **Physiological fasciculation (benign fasciculation):** This can occur in many normal persons, particularly in the calves, hands, periocular or paranasal muscles. They can be almost constant for days or weeks on ends, or even for years in some individuals. There is no weakness, wasting or signs of lower motor neuron lesion. They are usually annoying to the patient and are of multiple sites. Certain quantitative features of fasciculation such as brief duration and consistent pattern of firing favor benign over pathologic discharges. The voluntary motor unit potentials (MUPS) and fasciculation potentials are normal. The fasciculation potentials usually have three to five phases, a duration of 5-15 msec (some what less in the facial muscles), and an amplitude of several millivolts. The fasciculation potentials are evidence of motor nerve fiber irritability, and not of nerve fiber destruction or motor units denervation.
- b. **Pathological fasciculation:** It indicates destruction of the anterior horn cells, or irritation of the anterior root, when the fasciculation is very coarse and repetitive in muscles having the same root supply. Both voluntary MUPS and fasciculation potentials may be of long duration (> 15 msec)

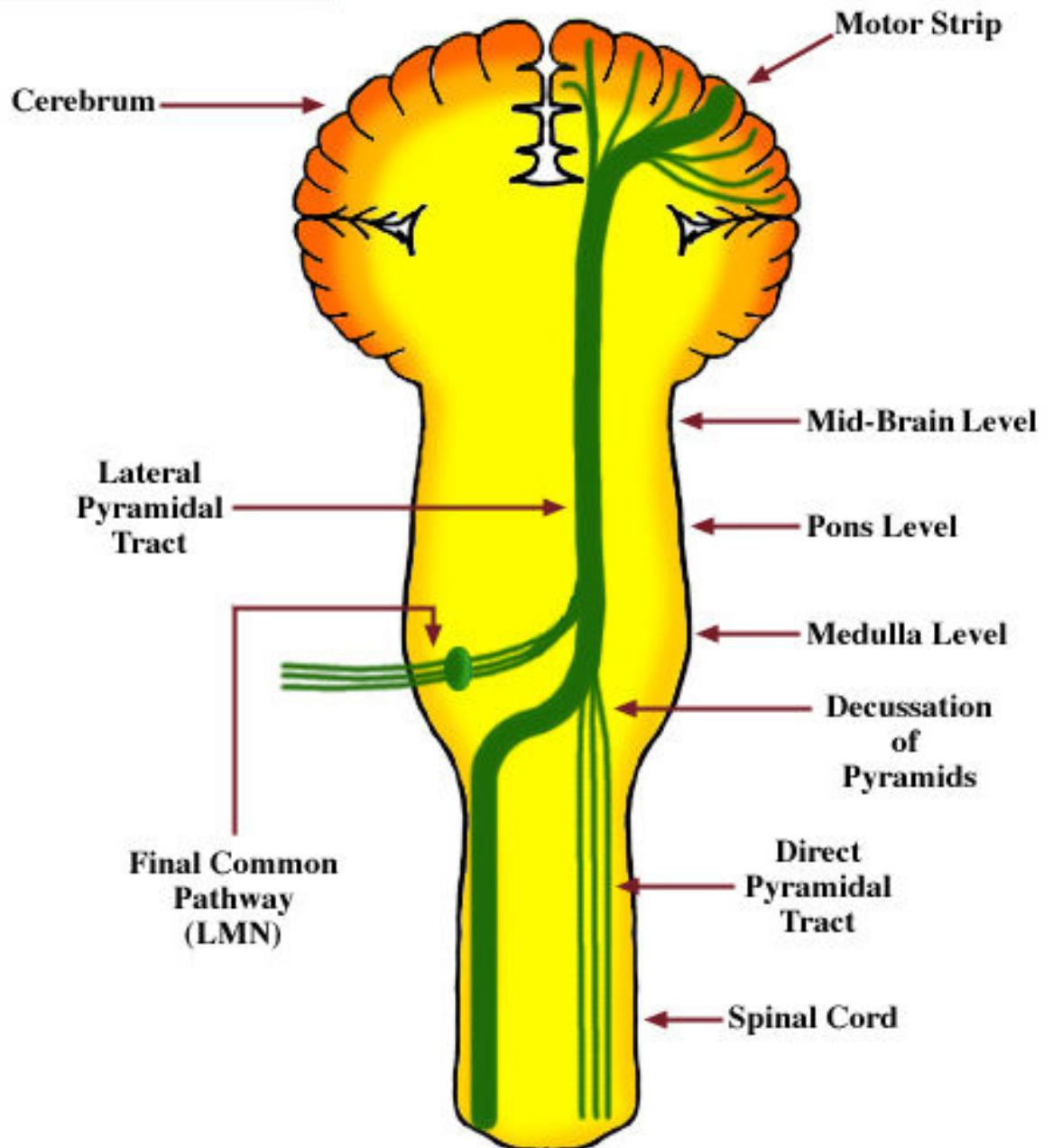
and of increased amplitude, indicating chronic denervation and re-innervations.

Causes include:

1. Motor neuron disease.
2. Early stages of poliomyelitis.
3. Progressive spinal muscular atrophy.
4. Syringobulbia.
5. Prolapsed intervertebral disc.
6. Chronic nerve entrapment.
7. Polyneuropathies.
8. Collagen diseases.
9. Myositis.
10. Thyrotoxic myopathy.
11. Syphilitic amyotrophy.
12. Peroneal muscular atrophy.

The pyramidal tract (an upper motor neuron) and the motor units (lower motor neuron) are well illustrated at page 123.

PYRAMIDAL TRACT

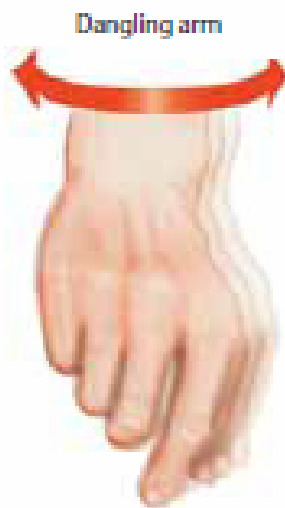

Abnormal movements (involuntary movements)

In a number of different diseases of the nervous system, involuntary, unintended movements occur, either at rest or during voluntary movements. The different clinical varieties of involuntary movements are not specific disease entities, but represent clinical pattern of involuntary movements. Most are due to diseases of the basal ganglia and the extra pyramidal system.

Methods of examination

1. Observe the patient carefully while talking to him for any abnormal movement in the upper limb, lower limbs, face, head and neck.
2. Give the patient specific instructions to bring out these abnormal movements more clearly. If the abnormal movements can not be seen by the examiner and only reported by the patient or his family. Then ask the patient about the time of occurrence, the posture and the exact situation of their occurrence. The instructions given to the patient to bring out certain movement must be tailored for each abnormal movement e.g., tremor, must be examined at rest, certain postures and at volition. Pictures at pages 125, 126 and 127 from the color atlas of neurology, shows different types of involuntary movements. The important involuntary movements are:
 1. Epilepsy, myoclonus
 2. Tremor.
 3. Athetosis, psedoathetosis
 4. Chorea.
 5. Dyskinesia.
 6. Dystonias.
 7. Hemiballismus.
 8. Torticollis.
 9. Tics.
 10. Myokymia.
 11. Tetany.
 12. Titubation.



Rest tremor



Kinetic tremor

Action tremor



Intention tremor (end tremor)

Tremor types

- Physiological tremor
- Essential tremor
- Parkinsonian tremor
- Orthostatic tremor
- Cerebellar tremor
- Holmes tremor
- Neuropathy-related tremor
- Substance-induced tremor*
- Palatal tremor
- Voice tremor
- Writing tremor
- Psychogenic tremor

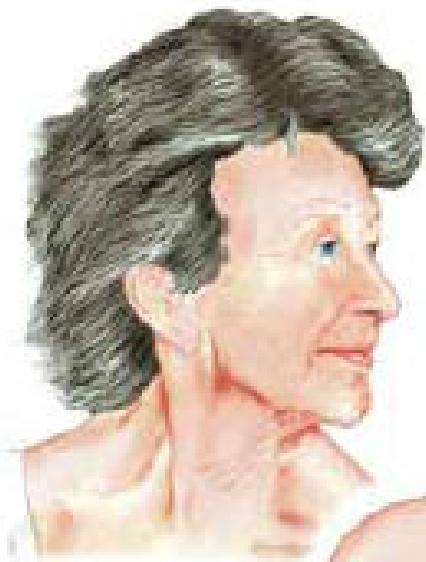*Due to coffee, tea, alcohol, medications (stimulants, neuroleptics, antidepressants, anti-convulsants, cyclosporine A), neurotoxins (heavy metals, insecticides, herbicides, solvents)



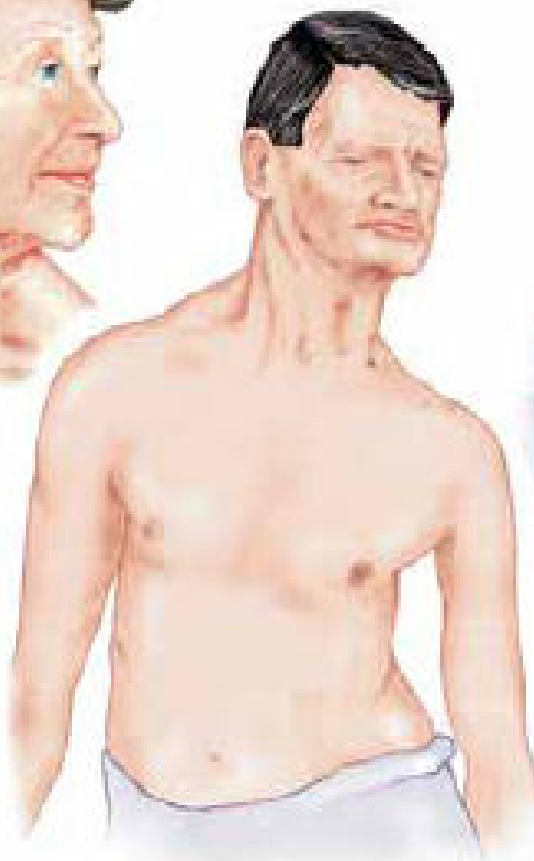Blepharospasm



**Craniocervical dystonia
(Meige syndrome)**



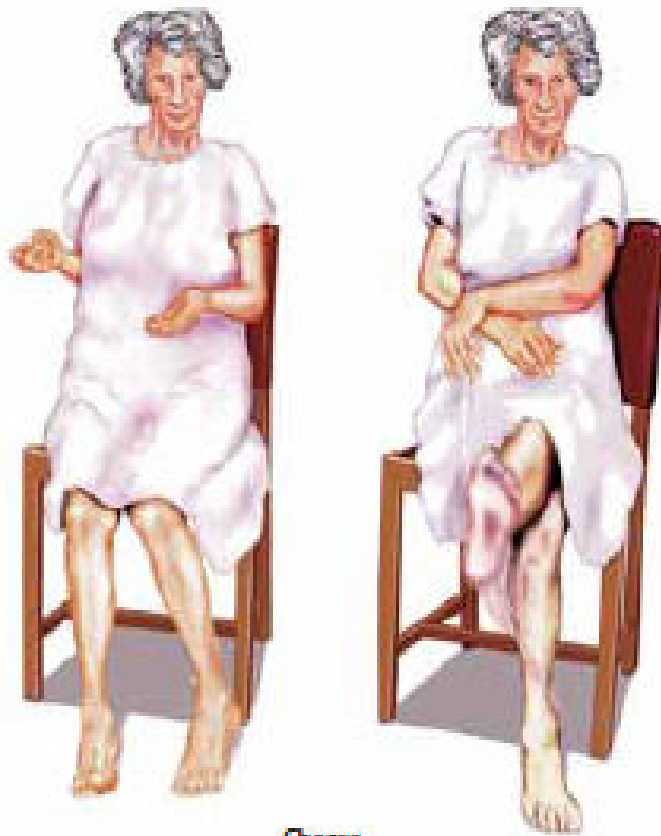**Cervical dystonia
(torticollis)**



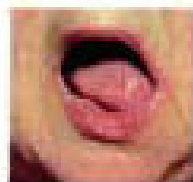
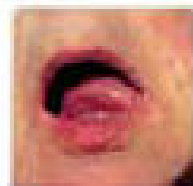

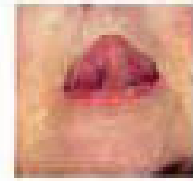
Multifocal dystonia (axial dystonia, "Pisa syndrome")



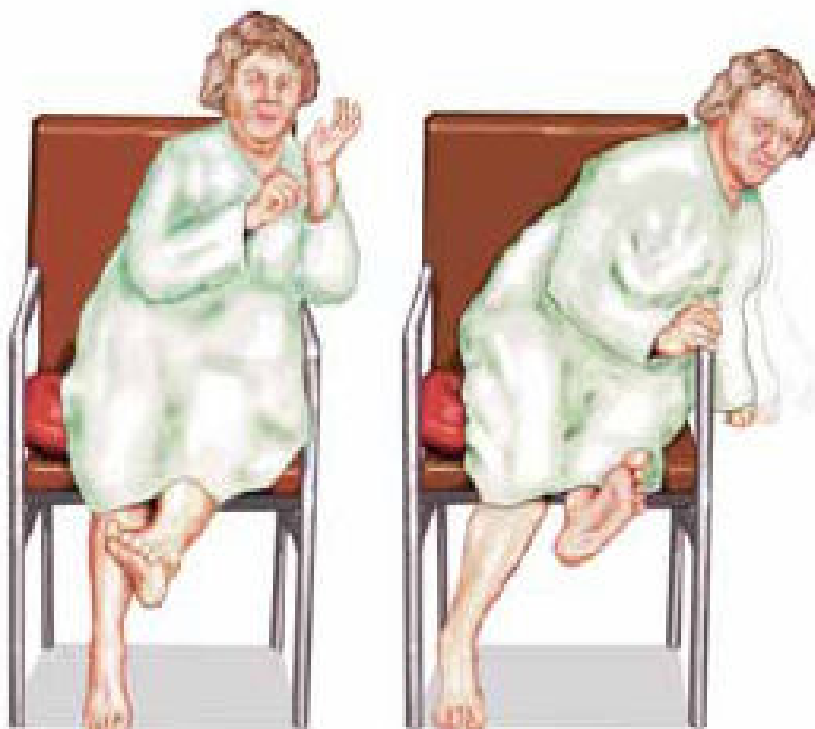**Writer's cramp
(= graphospasm)**



Chorea



**Orofacial
(buccolingual)
dyskinesia**



Hemiballism (left)

Abnormal postures

Formal testing of posture is usually postponed to the end of the examination together with stance, spinal movement and gait. At this stage of motor system examination, it is worthy to look for the following abnormalities of posture, while the patient is still in bed:

1. Pyramidal posture: the arm on the affected side is usually held flexed and adducted while the leg is usually extended and inverted. This posture is typical of pyramidal weakness due to cortico-spinal lesion.
2. Foot drop: Failure of the dorsiflexion of foot due to common peroneal nerve lesion, root lesion at (L5) or rarely due to central lesion.
3. Wrist drop: Due to radial nerve injury or root lesion at (C7).
4. Claw hand: Due to ulnar nerve lesion or root lesion at (C8, T1).
5. Pes cavus: High plantar arch which may be associated with inherited peripheral neuropathy.
6. Other sustained postures like dystonias, torticollis are mentioned under the title of involuntary movements.

3-1- 2: Muscle Tone

Definition: It is the resistant of muscles to passive movement of a joint. Tone depends on the degree of muscle contraction which depends, in turn, on the activity of anterior horn cells, which is governed by spinal and supra-spinal mechanisms.

Methods of examination

Testing tone in the upper limb

1. First pick up the patient's hand and forearm as if to take the pulse, holding his fingers in the right hand.
2. Then proceed to passive flexion and extension of the wrist, elbow and the shoulder, all movement must be gentle. Vigorous and violent movements are quite useless.

3. Now raise each arm in turn and let it fall back on to the bed, comparing (on the 2 sides) the checking movement which usually breaks the fall. This is of value in stuporous and uncooperative patients as well.

Testing the tone in the lower limb

- I. First gently roll the limbs with the palms of the hands on the shins. This gives an initial assessment of the tone and also encourages relaxation of the patient.
- II. Then proceed to passive flexion and extension of the hip, knee and ankle.
- III. Lastly raise the lower leg as one piece and allow it to fall, noting the normal checking movement.

Results of examination

- I. **Hypertonia:** two types of increased tone can be distinguished:

1- Spasticity

It consists of an increase in tone that affects different muscle groups to different extent. In the arms, tone is increased to a greater extent in the flexor muscles than in the extensors, while in the legs; tone is increased to a greater extent in the extensor muscles than in the flexors. Moreover, the resistance is usually most noticeable when the movement is first made and then suddenly overcome, producing the so called "clasp knife" Spasticity, most easily demonstrated at the elbow and the knee joints. Affected muscles are compact at rest, feel firm, do not flap at palpation and tend to form contractures. The increase in tone is velocity dependant, so that passive movement at a high velocity (sudden, unpredicted flexion, of a big joint) may be met with increased resistance.

Spasticity is caused by an upper motor neuron lesion, such as stroke that involves the supplementary motor cortex or the cortico-spinal tract. Spasticity may not become apparent for several days following the onset of an acute lesion.

2- Rigidity

Rigidity consists of increased resistance to passive movement that affects agonist and antagonist muscle group equally. The term "lead pipe" rigidity is sometimes used for descriptive purposes, while "cog wheel" rigidity is used when there are interruptions in the passive movement which probably relate to the underlying tremor. In general, rigidity indicates extra-pyramidal dysfunction and is due to a lesion of the basal ganglia e.g. Parkinson's disease.

II. Hypotonia (flaccidity)

This is characterized by excessive floppiness-a reduced resistance to passive movement-so that the distal portion of the limb is easily waved to and fro when the extremity is passively shaken. In hypotonic limb, it is often possible to hyperextend the joints and the muscle belly may look flattened and feels less firm than usual. While hypotonia usually relates to pathologic involvement of the lower motor neuron supply to the affected muscles, it can occur in the following conditions:

- Lesions of the muscle itself: Myopathies, benign infantile hypotonia, myasthenia gravis.
- State of neurological shock: It occurs in the earliest stages of a severe cord lesion, or profound hemiplegia. It is temporary unless destruction is extreme.
- Cerebellar lesions: ipsilateral hypotonia is common, but rarely very marked.
- Chorea: As in Sydenham's chorea, Huntington's disease.

III. Paratonia

Some patients give the impression of being unable to relax, and will move the limb being examined as the physician moves it, despite instruction to the contrary. In more advanced cases, there seems to be rigidity when the examiner moves the limb rapidly but normal tone when the limb is moved

slowly. This phenomenon-paratonia- is particularly apt to occur in patients with frontal lobe or diffuse cerebral disease.

3-1- 3 Muscle Power

Examination of the upper limbs

- I. Ask the patient to hold his arm outstretched in front of him and then to close his eyes. This is useful as a screen for:
 - a. Weakness of the shoulder abduction (C5)-the arm will drift down.
 - b. Cerebellar lesion: the arm on the affected side tends to hyperpronate and to rise above the other arm.
 - c. Loss of joint position sense: The affected arm tends to drift away from the other. (Equivalent of Romberg's test in the leg).
 - d. Pronator sign: now ask the patient to hold his arm outstretched and supinated in front of him. The arm on the affected side tends to hyperpronate and drift down. This indicates pyramidal weakness.
- II. Now proceed rapidly, through the muscle groups, starting proximally from the shoulder downwards, remembering that for each of the basic movement there is single root value and peripheral nerve supply.

Action	Notes
"I am going to test the strength of some of your muscles"	
Hold your arm out to your sides, like this now keep them up and don't let me stop you.	Shoulder abduction Supraspinatus, Deltoid Root C5
Now push them in toward you don't let me stop you	Shoulder adduction. Pectorals-C7
Pull your arm up towards you and don't let me stop you	Arm flexion, Biceps-C5 musculocutaneous nerve
Now push me away	Arm extension, Triceps-C7 (radial nerve)
Clench your fists and bend your wrists up toward	Wrist flexors-C7 (median

you, don't let me stop you.	and ulnar nerve)
Now push the other way	Wrist extensor-C7 (radial nerve)
Grip my fingers tightly (use 2 of your fingers)	Long and short flexors- C8,T1 (median and ulnar nerves)
Put your hand down flat, like this (palm upward)..., and point your thumb towards your nose. Now keep it there and don't let me push it down.	Thumb abduction-abductor pollicis brevis. Median nerve-C8, T1.
Spread your fingers wide apart and don't let me push them together.	Finger abduction Dorsal interossei Ulnar nerve-T1.
Now hold this piece of card between your fingers and don't let me pull it away.	Finger adduction Palmar interossei Ulnar nerve-T1.

III. As a minimum, without the benefits of asking the patient which muscle is weak, test:

Movement	Root supply	Nerve supply
Shoulder abduction	C5	Suprascapular, axillary.
Elbow flexion (with forearm half supinated)	C6	Radial
Wrist extension	C7	Radial
Thumb opposition	C8	Median
Finger abduction	T1	Ulnar

V1. Describe any weakness in terms of the Medical Research Council Scale:

Grade (0)	No movement.
Grade (1)	Flicker of movement on voluntary contraction.
Grade (2)	Movement present but not against gravity.
Grade (3)	Movement against gravity but not against resistance.
Grade (4)	Movement against resistance but not in full strength.
Grade (5)	Full strength movement.

Examination of the lower limbs

- I. Test power in muscles group (start proximally), most muscles have a nerve supply derived from 2 roots, so weakness is often difficult to detect in an individual root lesion.

Action	Notes
I am going to test the power of some of the muscles in your legs	
Keep your leg straight and lift it up into the air. Now keep it up and don't let me stop you	Hip flexion: Iliopsoas-L1,2. Femoral nerve
Now push your leg down into the bed and don't let me stop you.	Hip extension: Gluteus maximus L4,5 Inferior gluteal nerve
Push out against my hand	Hip abduction: Gluteus medius and minimus L4, 5-superior gluteal nerve.
Push in against my hand	Hip adduction, Adductor group-L2, 3, 4. Obturator nerve
Bend your knee and pull your heel up toward you, don't let me stop you (hold ankle)	Knee flexion Hamstrings-L5, S1. Sciatic nerve
Now straighten your knee out	Knee extension. Quadriceps-L3,4 Femoral nerve
Pull your foot up to you and don't let me stop you	Ankle dorsiflexion: Tibialis anterior and long extensors-L4, 5. Peroneal nerve.
Push your foot down against my hand	Ankle plantar flexion:Gastrocnemius-S1,2 Tibial nerve.
Push your foot out against my hand	Eversion of foot.Peronei-L5, S1. Peroneal nerve.
Push your foot in against my hand	Inversion of foot: Tibialis posterior-L4 Tibial nerve.

II. AS minimum test

Movement	Root supply	Nerve supply
Hip flexion	L2,3	Femoral nerve
Knee extension	L3,4	Femoral nerve
Foot dorsiflexion	L4,5	Peroneal nerve
Knee flexion	L5, S1	Sciatic nerve
Foot plantar flexion	S1,2	Tibial nerve.

- III. Any weakness should be described in term of the Medical Research Council Scale for purpose of uniformity of weakness description in the language of different examiners.

Patterns of muscle weakness

- 1- Pyramidal weakness: It affects particular movement rather than particular muscles, and is most marked in the abductors and extensors of the upper limbs, and flexors of the lower limbs. Distribution is more distal than proximal, particularly in the upper limb, where hand movements are affected earliest.
- 2- Proximal weakness: This pattern is commonly encountered in myopathies like:
 - a. Polymyositis, Myasthenia gravis.
 - b. Metabolic myopathies (hypokalemia, thyrotoxicosis, hypocalcaemia).
 - c. Muscular dystrophy like pelvic girdle dystrophy.
 - d. Radiculopathies (C5 in the upper limb, L1-L2 in the lower limb, diabetic amyotrophy).
 - E. Carcinomatous neuromyopathy.
- 3-Distal weakness: This is commonly encountered in peripheral neuropathies and radiculopathies that involve the distal parts like C8, T1 lesions in the upper limb, or cauda equina lesions in the lower limb.
- 4-Radicular weakness: It means that the weakness is limited to the muscles having that segmental supply e.g. disc prolapse at L5, S1 level lead to weakness which respect S1 root. This involves weakness of plantar flexion, loss of sensation at S1 dermatome and loss of ankle jerk.
- 5-Isolated peripheral nerve weakness: It means loss of the function of that nerve (mononeuropathy). This is commonly encountered in vasculitis, trauma, entrapment and inflammatory neuropathies e.g. are: foot drop, wrist drop due to radial nerve and peroneal nerve lesion respectively.

3-1-4 Reflexes

1- Tendon reflexes

These are monosynaptic stretch reflexes, elicited by tapping the tendon of a lightly stretched muscle with a reflex hammer. Each reflex depends on the integrity of the afferent and the efferent pathways, and the excitability of the anterior horn cells in the spinal segment of the stretched muscle. Properly performed, examination of the tendon reflexes offers a reliable and reproducible method of assessment of this system of neurons and their higher connections. It is therefore very important to become skilled in the techniques for eliciting these reflexes.

Prior requisites:

- 1- A good percussion hammer.
- 2- An examiner with flexible wrists who allows the weight of the hammer to decide the strength of the blow.
- 3- A patient who is warm, comfortable and relaxed.
- 4- A muscle placed in the optimum position, slightly on stretch, but with plenty of space for contraction.
- 5- When examining the tendon reflexes in the legs, care is taken to allow the patient's genitalia to be properly covered.

Methods of examination

The upper limbs

- Position of the limbs: The patient is slightly propped up, the elbow slightly flexed. The hand lying loosely across the abdomen, the fingers just not touching. In this position, the biceps and supinator jerks can be tested.
 - a. The biceps jerk (C5, C6/ musculo-cutaneous nerve):
 - Technique: Press the forefinger gently on the biceps tendon and then strike your finger with the hammer.
 - Normal results: Flexion of the elbow and visible contraction of the biceps muscle.

- b. The supinator jerk (C5, C6/ radial nerve):
 - Technique: Strike the lower end of the radius about 2 inches above the wrist. Watch for the movement of the forearm and fingers.
 - Normal results: Contraction of brachio-radialis and flexion of the elbow.
- c. The triceps jerk(C7/ radial nerve):
 - Technique: By holding the patient's hand, draw the arm across the trunk and allow it to lie loosely in the new position. Then strike the triceps tendon 5 cm (2 inches) above the elbow. If no response, repeat 2 or 3 times.
 - Normal results: Extension of the elbow and visible contraction of the triceps muscle.
- d. The finger flexion reflex (C8, T1/ median nerve):
 - Technique: Allow the patient's hand to rest palm upwards, the finger slightly flexed. The examiner gently interlocks his fingers with the patient and strikes them with the hammer.
 - Normal results: Slight flexion of all fingers and of the interphalangeal joint of the thumb.

The lower limbs

Position of the limb: The patient should lie in the same position as described for the upper limbs, but care should be taken to see that the legs do not touch the end of the couch.

- a. The knee jerk (L3, L4/femoral nerve):
 - Technique: The examiner hand is passed under the knee to be tested and placed upon the opposite knee. The knee to be tested rests on the dorsum of the observer's wrist. The patellar tendon is struck midway between its origin and insertion. Alternative way is to put the left arm under both knees in order to flex them together, and then strike the patellar tendon on each side increasing the strength if there is no response. This is especially important

for purpose of comparing the two sides. Watch the movement of the lower leg and of the quadriceps muscle.

- Normal results: Extension of the knee and visible contraction of the quadriceps.
- b. The ankle jerk:
 - Technique: Place the lower limb in the bed, so that it lies everted and slightly flexed, then, with one hand, slightly dorsiflex the foot to stretch the Achilles' tendon and with the other hand strike the tendon on its posterior surface.
 - Normal results: Plantar flexion of the foot and contraction of the gastrocnemius.

Examination with reinforcement

This maneuver must be done whenever the reflexes are absent, because absent reflexes is not necessarily pathological. This situation is often found in patients involuntarily tensing themselves, and those very relaxed, such as a happy young child, and probably in very muscular individual. If other muscles are placed under strain, it often becomes possible to obtain a normal reflex.

For the upper limbs, the patient should clench his teeth tightly, or while one arm is being examined, he should clench the fist of the other.

For the lower limbs these measures can still be used, but the well tried method of **Jendrasssek** is more reliable. The patient interlocks the flexed fingers of the two hands and pulls one against the other at the moment the reflex is stimulated. Whatever the method used, the patient should make the movement at the moment that the reflex is tested and relax afterwards.

Clonus

This phenomenon must be done whenever the reflexes are exaggerated as a result of cortico-spinal lesion:

- a. Ankle clonus: Bend the patient's knee slightly and support it with one hand, grasp the forepart of the foot with the other hand and suddenly dorsiflex the foot. This sudden stretch causes a brief reflex contraction of the calf muscle,

which then relax, continued stretch causes a regular oscillations of contraction and relaxation, which is called clonus. **Sustained clonus** is abnormal, and it is evidence of an upper motor neuron lesion. It is then always associated with increased tendon reflexes and an extensor plantar response. **Unsustained clonus** may occur in healthy persons, particularly in those who are very tense or anxious, in those subjects the plantar responses are flexors.

- b. Patellar clonus: It has the same significance of the ankle clonus. It is done by grasping the patella of the extended and relaxed knee and suddenly pressing it down. This will initiate regular oscillation of the patella in an up and down direction.

Grading of tendon reflexes

Absent with reinforcement	(0)
Hyporeflexia	(+)
Normal	(++)
Brisk	(+++)
Clonus	(++++)

Abnormalities of tendon reflexes

- a. Areflexia
- b. Hyper-reflexia
- c. Reflex asymmetry.

a. Areflexia

Reflexes appreciably reduced or absent in normal individual become normal on reinforcement. Pathologically, reduction occurs under the following conditions:

- i. When there is a pathology in any part of the reflex arc e.g. lesion of the afferent part as in polyneuritis, tabes dorsalis, the anterior horn cells (poliomyelitis), the anterior root (spinal compression), the efferent part (trauma, peripheral neuropathy), the muscle itself

(myopathies, periodic muscle paralysis). There are, of course, many other possible disorders at these different sites.

- ii. Spinal shock.
- iii. Advanced rigidity, Spasticity, or muscle contracture..
- iv. Cerebellar disease.
- v. Deep coma.

b. Hyper-reflexia

This occurs with upper motor neuron lesions at all levels above the anterior horn cells. It may occur with anxiety or nervousness, in thyrotoxicosis, and as a manifestation of tetanus. Hyper-reflexia is therefore only of pathological significance, if it is asymmetrical or associated with other signs of upper motor neuron lesion.

c. Reflex asymmetry

Although the intensity of reflex responses varies considerably among subjects, reflexes should be symmetrical in any individual. Several points can be made regarding reflex asymmetries:

- 1- Lateralized asymmetries of response i.e. the reflexes that are brisker on one side of the body than on the other side. It usually indicates upper motor neuron disturbance.
- 2- Focal reflex deficit often related to root, plexus, or peripheral nerve lesion, e.g. unilateral depression of the ankle jerk commonly reflect an S1 radiculopathy resulting from a lumbosacral disc lesion.
- 3- Loss of distal tendon reflexes (especially the ankle jerk) with preservation of more proximal ones is common in polyneuropathy.

Other important reflex abnormalities:

- ☒ **The inverted supinator jerk:** With lesions at C5 c6, the supinator reflex or biceps reflex may be lost, but, when it is tested, brisk flexion of the finger is seen. In practice, this is usually associated with exaggerated triceps reflex. The inverted supinator reflex indicates cord lesion at the fifth or sixth cervical level, causing a lower motor neuron lesion of C5

and an upper motor neuron lesion of reflexes innervated below this level. It is very common in cervical disc disease, syringomyelia, and cervical trauma and sometimes in the cervical neoplasm. It is invaluable in localizing lesions responsible for a spastic paresis which have no sensory abnormality or clear cut sensory level. This applies particularly to cervical spondylosis.

☒ **Extended pyramidal reflexes:** In hyper-reflexic states, there may be spread of the region from which a particular reflex response can be elicited. For example, elicitation of the biceps or triceps reflexes may be accompanied by reflex finger flexion. This indicates that the lesion is above the level of the reflex which is tested, in this example it is above C5.

☒ **Cross adduction:** It means that the reflexes are more exaggerated on the side where adduction occurs.

1. Superficial reflexes

For practical purposes, only 2 of the many superficial reflexes are routinely tested - the abdominal reflexes and the planter reflexes.

i. The polysynaptic superficial abdominal reflexes

They depend on the integrity of the T8-L2 spinal cord segments. They are elicited by gently stroking each quadrant of the abdominal wall with a blunt object such as a wooden stick or a key. A normal response consists of contraction of the muscle in the quadrant stimulated, with a brief movement of the umbilicus toward the stimulus. Asymmetric loss of the response may be of diagnostic significance.

1. The response may be depressed or lost on one side in patients with an upper motor neuron lesion above the upper level of the segmental innervations. This is more common in spinal lesions (ipsilateral or bilateral) than in cerebral lesions (Contralateral) but the reflexes are not necessarily absent in all such cases.

2. Segmental loss of the response may relate to a local disease of the abdominal wall or its innervations, as in radiculopathy, herpes zoster or surgical operation that damaged the peripheral nerves or the muscle itself.
3. The cutaneous abdominal reflexes are frequently absent bilaterally in the elderly, in the obese, in multiparous women, in patient who have had abdominal surgery and defect of technique, relaxation or observation.

ii. **The plantar reflex**

This is the most important reflex in the body, and yet the most frequently misinterpreted.

Technique: Start by positioning the patient so that the knee is slightly flexed and the thigh is externally rotated. The outer aspect of the foot should rest on the couch as for testing the ankle jerk. Warn the patient that the sole of the foot will be scratched and ask him to try to let his foot remain loose. The outer aspect of the sole is then firmly stroked with a blunt point such as the key. The stimulator should move forwards and then curves inwards toward the middle metatarso-phalangeal joint. The stimulus must be firm, but not frankly painful. Do the stimulation slowly and allow yourself time to see what happening.

Watch the first movement of the metatarso-phalangeal joint of the great toe, which is in this position is immediately visible. Watch also the movement and behavior of the other toes. The test should now be repeated with the knee in extension, and in case of doubt the knee may even be pressed downwards, in this new position, early abnormalities may be detected which disappear when the knee is flexed. The two methods serve as a check for each other.

Normal results: Normally no matter what's shape may be, the great toe will flex at the metatarso-phalangeal joint, even if the terminal joint appears to extend. At the same time, the other toes will flex and close together. The true reflex movement normally does not start when the stimulus started, but when the instrument is about one third of the way along the foot, or sometimes not until the end of the movement.

The Babinski response: It consists of dorsiflexion of the big toe and fanning of the other toes in response to stroking the lateral border of the foot, which is in part of S1 dermatome, flexion of the hip and knee may occur. Such an extensor plantar response indicates an upper motor neuron lesion involving the contralateral motor cortex or the cortico-spinal tract; it can also be found in anesthetized or comatose subjects, in patients who have had seizure, and in normal infants. Complete paralysis of the extensors of the toes may make Babinski's response impossible. This is only rarely of importance, however, for such total paralysis is likely to be of lower motor neuron origin. The contraction of the tensor fasciae latae must be observed. An extensor plantar response can also be elicited, though less reliably, by many other maneuvers like the followings:

- 1- Bing's sign: Pricking the dorsal surface of the big toe with a pin.
- 2- Oppenheim's maneuver: Firmly stroking down the anterior border of the tibia from knee to ankle.
- 3- Gordon's maneuver: Squeezing the calf muscle.
- 4- Schafer's maneuver: Squeezing the Achilles tendon.
- 5- Chaddocks maneuver: Stroking the back of the foot just below the lateral malleolus.
- 6-Gondas maneuver: flickering the little toe.

In interpreting the responses, attention must be focused only on the direction in which the big toe first moves.

3-1-5 Coordination

Coordinate movement needs intact motor, sensory, cerebellar, extra pyramidal, proprioceptive, vestibular and visual functions. Lesions or disturbances of these systems may therefore produce inco-ordination. In this chapter, examination of cerebellar function is the main concern. Incoordination or ataxia due to other conditions can easily be separated or differentiated from cerebellar disorders.

Tests of coordination (cerebellar functions) in the upper limbs

1- Finger-nose test:

Ask the patient first to touch his nose, then your forefinger with his index finger, first with one hand and then the second hand. Look for the following cerebellar signs:

- i. Intention tremor: It is more evident as the finger approaches the nose.
- ii. Dysmetria: It means overshooting of the target. In this test, the patient will shoot the finger past the nose, to the cheek or the ear.
- iii. Dyssynergia: It denotes the breakdown of complex actions into the individual movements composing them; the patient may first flex the elbow and then bring the hand up to the nose instead of combining the movements into one action.

2- Rapid alternating movements:

- Ask the patient to strike his thighs rhythmically.
- Ask him to flex his elbows to a right angle and then alternatively to supinate and pronate his forearms as rapidly as possible as though screwing in a light bulb.
- Other many maneuvers, which may include rapid alternating movement between palms and back of the hands, rapidly touching the thumb to each finger in succession.
- Dysdiadochokinesia: It is the technical term for dysrhythmia in performing any of these tasks. In practice dysrhythmia due to cerebellar disease means any change in rate, rhythm, or amplitude of the movement.

3- Rebound phenomenon: The patient flexes an arm as strongly as possible, or holds his arm extended against resistance. The examiner then suddenly lets go, if the arm flies up towards the face, this signifies that the patient is unable to check the abrupt imbalance between flexors and extensors. This is a solid cerebellar sign.

Tests of coordination in the lower limbs

1- Heel-Knee-Shin test:

Ask the patient to lift one leg high in the air, to place the heel on this leg on the opposite knee, and then to slide the heel down his shin towards the ankle. The test is then repeated on the other side. In cerebellar ataxia, a characteristic, irregular, side to side series of errors in the speed and direction of movement occurs. The test must be performed with the eyes open.

2- Gait examination:

- a. If the patient is able to walk, a good test of lower limb coordination consists of asking him to walk along a straight line. If in coordination is present, he will soon deviate to one side or the other. Watch particularly for unsteadiness as he turns to walk back towards you.
- b. Tandem walk: Ask the patient to walk along straight line on the floor placing the heel of one foot immediately adjacent to the toe of the one behind. This test is more difficult than the first test, and it can usually disclose minor degrees of unsteadiness. See pictures at page 146.

C. Comb test: Ask the patient to walk to a known point and then to return back to the original place. In patient with cerebellar lesion he will continuously deviate to the side of the lesion until he finally makes a comb.

Cerebellar signs in the upper limbs

They are divided into specific and non specific signs.

I. Specific signs:

- Intention tremor.
- Dysmetria.
- Dysynergia.
- Dysdiadochokinesia.
- Rebound phenomenon.

II. Non specific signs.

*Hypotonia

*Hyporeflexia

Differential diagnosis of cerebellar ataxia

❖ Acute ataxia:

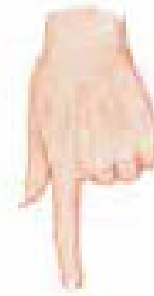- 1- Drug intoxication: Ethanol, sedatives, hypnotics, anticonvulsants, hallucinogens.
- 2- Wernick's encephalopathy.
- 3- Vertebrobasillar ischemia or infarction.
- 4- Cerebellar hemorrhage.
- 5- Inflammatory disorders.

❖ Chronic ataxia:

- 1- Multiple sclerosis.
- 2- Alcoholic cerebellar degeneration.
- 3- Phenytoin induced cerebellar degeneration.
- 4- Hypothyroidism.
- 5- Paraneoplastic spino-cerebellar ataxia (SCA 1-7).
- 6- Frederick's ataxia.
- 7- Ataxia telangiectasia.
- 8- Wilson's disease.
- 9- Acquired hepatolenticular degeneration.
- 10- Creutzfeldt Jacob disease.
- 11- Posterior fossa tumor.
- 12- Posterior fossa malformation.



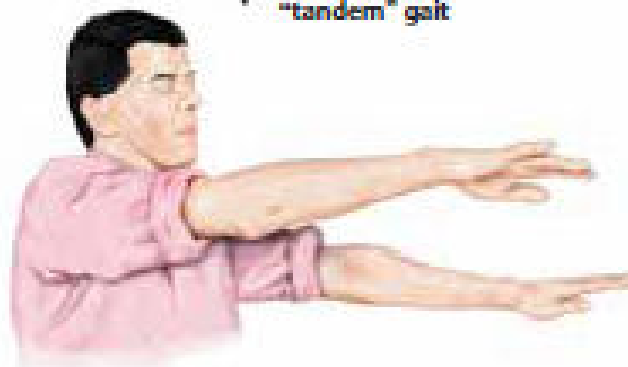Gait ataxia with
"tandem" gait



Finger-finger test
(intention tremor)



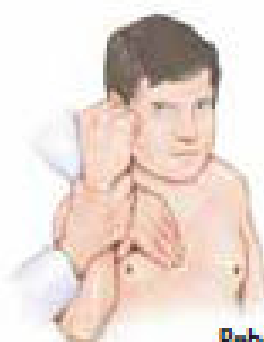Dysidiadochokinesis



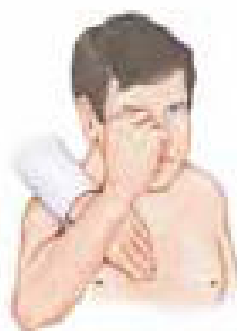Postural test for position
sense



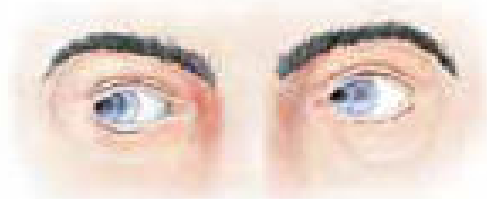Dysmetria (hypermetria)



Rebound phenomenon



Test for gaze-evoked nystagmus



Saccades; gaze-evoked and rebound nystagmus

3-2: Sensory System Examination

3-2-1 Principles of sensory system examination

A. Primary sensory modalities to be tested:

- 1- Light touch: It ascends through 2 tracts, posterior columns, and the anterior spinothalamic tract.
- 2- Pain and temperature: It travels in the lateral spinothalamic tract.
- 3- Vibration and joint position: It travels in the posterior columns.

B. Important anatomical landmarks:

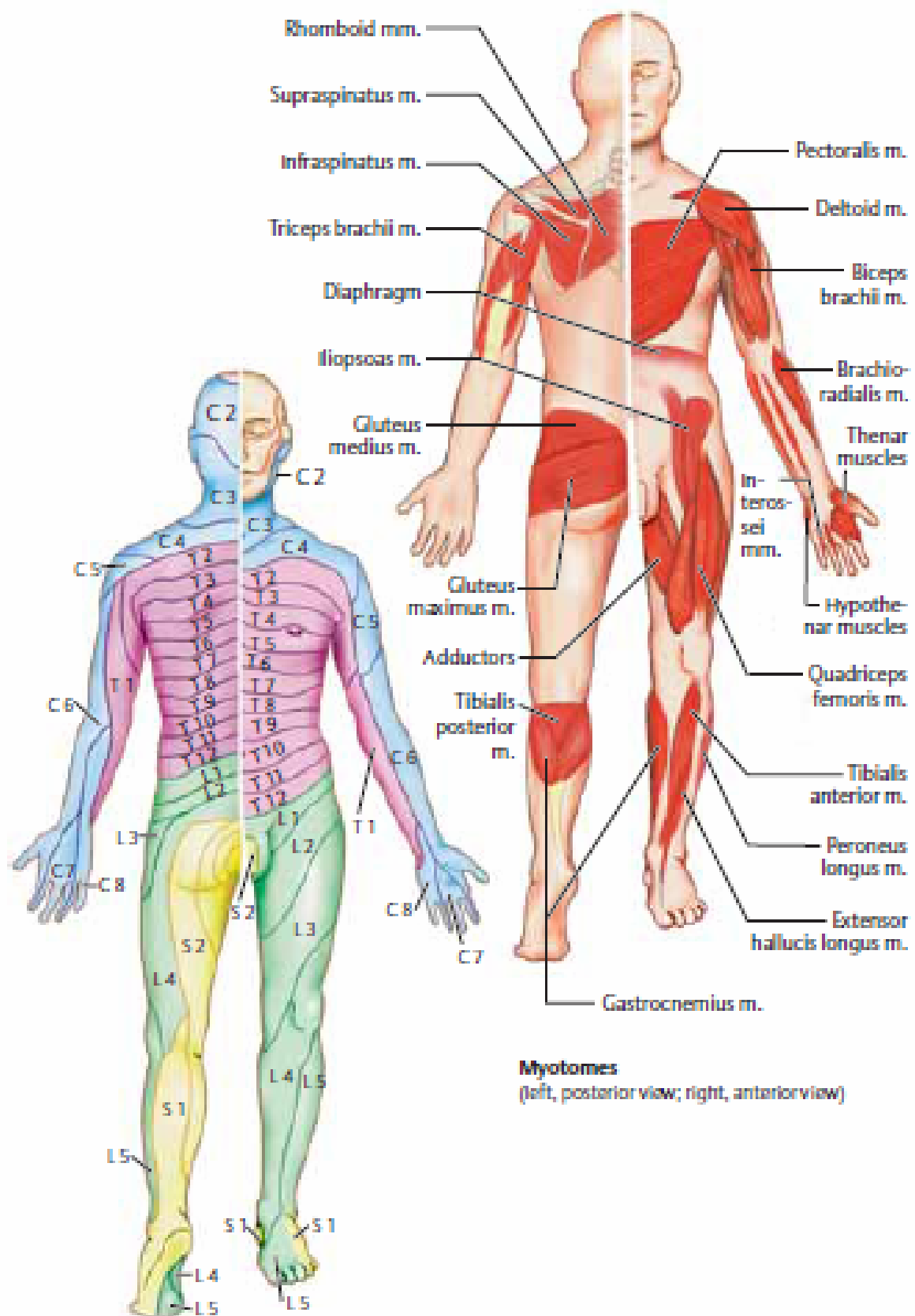
- 1- In the posterior columns: Fibers from the lower part of the body are displaced medially as more fibers enter, so the cervical spinal segments are the most lateral.
- 2- In the spinothalamic tract: Fibers from the lower part of the body are displaced to lie superficially to those from the upper part, so the cervical spinal segment are the most medial.
- 3- Ascending fibers from the reticular nuclei, medial lemniscus, trigeminal lemniscus, and spinothalamic pathways merge in the midbrain and terminate in the ventral posterolateral nucleus of thalamus.
- 4- Fibers subserving sensation from the head and face join with the contralateral medial lemniscus and spinothalamic tract in the upper medulla, pons and midbrain. The crossed trigeminal- thalamic and lateral spinothalamic tracts run together and a lesion at these levels causes loss of pain and temperature sense on the opposite half of the face and body.

C. Sensory dermatomes:

Be familiar with the cutaneous areas of the distribution of the spinal segments (dermatomes). Avoid testing at the periphery of these dermatomes for considerable overlap occurs. The followings are the important dermatomes Table (17. For more detail, look at the pictures below at page 148.

Table 17. Sensory dermatomes of the body

Dermatome	Served area
C2	Back of head, angle of jaw
C3	Neck
C4	Front and back of the upper chest
C5-T2	Upper limb
T4	Chest, at the level of the nipples (men)
T7	Chest, at the level of the lower ribs
T10	Abdomen, at the level of umbilicus
L1	Inguinal region
L2-S2	Lower limb
S3-4	External genitalia, buttocks in concentric rings.



Myotomes
(left, posterior view; right, anterior view)

Dermatomes (left, posterior view; right, anterior view)

The purposes of all sensory tests

- 1- To demonstrate clearly and consistently the limits of any area of abnormal sensation.
- 2- To determine which modalities are involved within those limits.
- 3- To compare the finding with known patterns of abnormal sensation.

3-2-2 Methods of examination of the sensory system

Pain

Pain may be evoked either by a cutaneous stimulus, e.g. prick of a pin, or by pressure on deeper structures like muscles or bones, superficial and pressure pain should be tested separately.

- 1- Superficial pain: It is tested by asking the patient to indicate whether a point of a pin feels sharp or blunt. Appreciation of pressure or touch of the pin point must not be confused with the appreciation of sharpness. The pin used should be an ordinary domestic pin, rather than hypodermic needle, the latter is designed to cut skin relatively painlessly and is thus not suitable for sensory testing.
- 2- Pressure pain (deep pressure): It is examined by squeezing the muscles or the Achilles tendon. Abolition of pressure pain is often the most prominent sensory disturbance in tabes dorsalis.

Absence of pain sensation is termed "Analgesia", partial loss of pain sensation is called "Hypoalgesia", and an exaggerated pain sensation, so that even a mild stimulus causes an unnatural degree of painful sensation, is called "Hyperalgesia".

Temperature sense

Temperature sense is conventionally examined by using test tubes containing warm and cold water. The part to be tested is touched with each in turn, and the patient says whether each tube feels cold or hot. At the bedside, it is

often sufficient to use the cold metallic sensation of the touch or the end of an ophthalmoscope or tuning fork for rough assessment of temperature sensation.

Touch sensation

Use a wisp of cotton wool or the tip of your index finger. Tell the patient to shut his eyes and to say "yes" each time he feels anything. The cotton wool is shaped to a point and the skin is lightly touched, but not too lightly. Touch sensation may be abolished or reduced "hypo aesthesia". Misperceived as painful, irritating or tingling sensation "hyperaesthesia", or mislocalized. Very rarely there may be a delay between the stimulus and its recognition by the patient. Areas of diminished sensation should be carefully delineated and recorded.

Vibration sensation

Vibration appreciation is evaluated with a tuning fork (128 Hz) that is set in motion and then placed over a bony prominence. If the patient perceives the vibration, ask him when he ceases to feel it. If the examiner can then still perceive it, the patient's perception of vibration is impaired. There is often some loss of vibration sense in the feet and legs in old ages. If there is distal loss of vibration, then the fork can be placed on more proximal bony prominence in the feet and arm. Placing it in turn on the spinous processes of the vertebrae and moving upwards until it is appreciated, on rare occasions, give the only clear sensory level of a posteriorly situated spinal tumor. The 2 sides are now compared, first by asking, if the degree of vibration feels the same, and then by comparing the promptness with which he notes the cessation of vibration after the examiner has just stopped the fork by touching it. Next allow the fork to run down by itself, asking the patient to say when he can feel it no longer. Move it then quickly to the other limb, where normally vibration will still be detectable for 3-5 seconds. In minor degrees of abnormality, it is not detected when transferred from normal to abnormal side, and persists longer than usual when moved from abnormal to normal side.

Position sense

Ask the patient to close his eyes. Explain that you will move his finger (or toe or elbow) up or down and ask him to tell you which way it has been moved. He should be able to recognize movement of only few degrees at all joints, including knee, ankle, elbow, and wrist, in addition to the more commonly tested fingers and toes. It is essential that the patient is relaxed and he allows the limb to be moved passively.

When position sense is disturbed in the upper limbs, the outstretched fingers may twist, rise and fall when held with the eyes closed, these involuntary movements (pseudoathetosis) usually disappear completely when the patient opens his eyes.

The appreciation of movement is closely related to the sense of position and can be tested at the same time. Gradually move digits into a new position, with the patient's eye closed, and ask him to say "now" as soon as he recognizes the movement. Movement of less than 10° can be appreciated at all normal joints.

Abbreviated (directed) sensory system examination

Examination of different sensory modalities in all sensory dermatomes of the body is both time consuming and little yield up. The following steps are directed to achieve sensory examination in a rapid, well oriented and to give a better idea about localization of different lesions involving the somatic sensory pathways. As a minimum check touch, pain, vibration and position senses in each of the following patterns:

A. If the examination of the motor system revealed signs of upper motor

neuron lesion: Then sensory examination is best tailored to the pattern of motor weakness:

- 1- Total hemi paresis: Check for hemi anesthesia by comparing the left and right sides of the body. The lesion must be above the medulla (in the upper brainstem, thalamus, or parietal lobe).

- 2- Crossed hemiparesis: Check for crossed hemisensory loss by comparing the left and the right side of body. This is nearly always indicating medullar lesion (Wallenberg syndrome).
- 3- Paraparesis, quadriparesis and no signs above the foramen magnum: Check for sensory level. If there is bilateral loss of all sensation below a definite level, this indicates a gross lesion of the spinal cord.
- 4- Unilateral spastic leg and /or arm and no signs above foramen magnum: Check for sensory level on the other side. If there is unilateral loss of pain and temperature sensation below a definite level, this indicates hemisection of the cord (the Brown-Sequard syndrome).

B. The motor system examination revealed signs of lower motor neuron lesion

- 1- Radicular weakness: Check for dermatomal sensory abnormalities by comparing the left dermatomes to the right dermatomes e.g. if the patient has disc prolapsed at right L5-S1, motor findings will be weakness in the plantar flexion of the foot and loss of ankle jerk. In this case sensory loss will respect S1 dermatome of the right side while the left is normal.
- 2- Distal weakness: Check for stocks and gloves pattern of sensory loss. This is usually indicating peripheral polyneuropathy.
- 3- Weakness which respect a nerve distribution: Check for sensory loss in the area supplied by that nerve e.g. a patient with drop wrist due to radial nerve palsy expected to has sensory loss over the dorsum of the thumb and the index finger, so check sensation in this area.
- 4- Pure lower motor neuron weakness of the lower limb plus sphincteric disturbance: Check for saddle anesthesia. This is the description given for impairment of sensation over the lowest sacral segment. It indicates a cauda equina lesion.

3-2-3 Patterns of abnormal sensation

The most common pattern of sensory abnormality are illustrated in this chapter, remembering that, though anatomical pathways may not vary, lesion do vary greatly, so that the intensity of the sensory abnormality may range from total loss to very slight reduction or even hypersensitivity, and it is in these latter cases that great experience is needed for judgment of the significance of any abnormality that may be found.

- 1- Total unilateral loss of sensation: This may include the following types:
 - a. Loss of all forms of sensation-----extensive lesion of the thalamus.
 - b. Loss confined to all exteroceptive sensation-----Due to partial lesion of the thalamus, or a lesion laterally located in the upper brainstem.
 - c. Loss confined to all proprioceptive sensation-----Caused by partial lesion of the thalamus, or a lesion medially located in the upper brainstem.
- 2- Loss of pain and temperature sensation on one side of the face and the opposite side of the body: This indicates a lesion of the medulla (Lateral medullary syndrome).
- 3- Bilateral loss of all forms of sensation below a definitive level: This indicates a gross lesion of the spinal cord. The upper level of the lesion may be indicated by a zone of hyperaesthesia. This should be taken as an indicator for the highest affected spinal segment. If the upper level is vague and there is no zone of hyperaesthesia, the actual level of the lesion may be many segments, higher than what the sensory level suggests. If pain and temperature only are affected, it will be the anterior aspect of the cord that is involved only.
- 4- Unilateral loss of pain and temperature sensation below a definitive level: This indicates partial unilateral lesion of the spinal cord (the Brown-Sequard Syndrome). It consists of ipsilateral motor and proprioceptive impairment and contralateral loss of pain and temperature, while at the highest level on

the side of the lesion there is a thin band of analgesia representing involvement of the root entry zone.

- 5- Impairment of pain and temperature sensation over several segments with normal sensation above and below: With a central cord lesion e.g. syringomyelia, trauma, and central cord tumors, there is characteristic loss of pain and temperature appreciation with sparing of other modalities. This loss is due to the interruption of fibers carrying pain and temperature that cross from one side of the cord to the spinothalamic tract on the other. Such a loss is usually bilateral, may be asymmetric, and involves only the fibers of the involved segments. It may be accompanied by lower motor neuron weakness in the muscles supplied by the affected segments and sometimes by a pyramidal and posterior column.
- 6- Loss of sensation of saddle type: This is the description given to impairment of sensation over the lowest sacral segments. If affecting all forms of sensation, accompanied by loss of leg reflexes and sphincter control, it indicates a major lesion of the Cauda Equina.
- 7- Loss of position and vibration sense alone: This indicates a lesion of the posterior columns which is often difficult to localize. If lost only below a definitive level, there may be compression of the posterior part of the cord. If the arms are affected to a much greater extent than the leg, and asymmetrically, the lesion may be due to a combination of cervical spondylosis and a very narrow vertebral canal; or to foramen magnum lesion, especially with tonsillar prolapse.
- 8- Loss of all forms of sensation over a clearly defined area in one part of the body only: This could be due to a lesion of sensory root, or of a peripheral nerve. To differentiate, comparison must be made with the known sensory dermatomes, and peripheral nerve distribution Table (18, 19). Table 20 gives the important clinical features, the site of lesions and the possible causes of sensory disturbances at different level in the ascending tracts.

Table 18. Sensory loss in the upper limb

Root/Nerve lesion	Distribution
C5	Lateral border of the upper arm
C6	Lateral forearm including the thumb
C7	Middle fingers
C8	Medial forearm including the little finger
T1	Axilla down to the olecranon
Axillary	Small area over the deltoid muscle
Musculocutaneous	Lateral forearm
Radial	Dorsum of the thumb and index finger or may be none
Ulnar	Medial palm, little and medial half of the ring fingers.
Median	Lateral palm and lateral 3 & 1/2 digits

Table 19. Sensory loss in the lower limb

Root/Nerve lesion	Distribution
L2	Across upper thigh, or may be none
L3	Across the lower thigh, or may be none
L4	Medial side of the leg
L5	Dorsum of the foot, big toe
S1	Behind lateral malleolus, back of the calf
Obturator	Medial surfaces of the thigh, often none
Femoral	Anteromedial surface of the thigh and leg to the medial malleolus
Peroneal	Dorsum of the foot or none
Tibial	Sole of the foot

3-3 The Gait

Methods of examination:

- 1- Ideally the patient foot should be bare, and his legs are exposed.
- 2- Ask him to walk away from you, turn and then walk back towards you.
- 3- See if he walks in a straight line; this can be rechecked by asking him to walk along a line on the floor, or heel to toe. If he falls or deviates, note to which side.
- 4- Decide whether the gait conforms to any of the classical types of abnormal gait, if so; look specifically for other features of those conditions. Pictures at page 161 demonstrate different types of gait abnormalities.

Gait abnormalities

- 1- **Hemiplegic's gait:** In patient with hemiparesis due to a corticospinal lesion, the selective weakness of antigravity muscles and spasticity lead to a gait in which the affected leg must be circumducted to be advanced. The patient tilts at the waist toward the normal side and swings the affected outward as well as forwards, thus compensating for any tendency to drag or catch the foot on the ground because of weakness in the hip and knee flexors or the ankle dorsiflexors. The arm on the affected side is usually held flexed and adducted. In mild cases, there may be no more than a tendency to drag the affected leg, so that the sole of that shoe tends to be excessively worn. Common causes include cerebrovascular accident.
- 2- **Paraplegic gait:** In bilateral upper motor neuron lesions, both feet drag, but there is also an adductor spasm causing the leg to cross each other and each foot to trip up the other. Such gait is commonly described as scissor gait. Common causes include: cerebral diplegia, advanced cervical spondylosis, multiple sclerosis, hereditary spastic paraplegia.
- 3- **Cerebellar gait** (drunken or reeling): In Cerebellar lesions the gait may be disturbed in several ways:

- a. Unilateral hemispheric lesion: the patient walks with his feet apart and arm outstretched, ready to hold onto any support that is available. He will not fall, but reels consistently to one side (the side of the lesion). The gait is equally severe with eyes open or closed.
 - b. Truncal ataxia: The patient is grossly unstable, reels in any direction, including backwards, and may need the support of two people. In extreme cases, he can not sit from the bed or can not stand without falling. This is seen in midline posterior fossa lesions, including tumors of the vermis, foramen magnum anomalies and cerebellar degeneration that can occur with alcoholism or hypothyroidism.
- 4- **Shuffling gait:** Difficulty in starting (frozen to the floor) or take time before beginning to walk, slow, shuffling gait with small steps, a slightly stooped posture of the trunk, and arm which are flexed at the elbow and do not swing. The patient appears to be continuously about to fall forwards (festination). He is unable to stop quickly when pushed forwards (propulsion) or backward (retropulsion), and finds it easier to walk on uneven ground.
- 5- **Apraxic gait:** It occurs in some patients with disturbances, usually bilateral, of frontal lobe function, such as may occur in hydrocephalus or progressive dementing disorders. There is no weakness or incoordination of limbs, but the patient is unable to stand unsupported or to walk properly. The feet seem glued to the ground. If walking is possible at all, the gait is unsteady, uncertain, and short-stepped, with marked hesitation (freezing), and the legs are moved in a direction inappropriate to the center of the gravity. At times, they halt, unable to advance without a great effort. Although, they do much better with little assistance or with exhortation to walk in step with the examiner. Causes include:
- i. Normal pressure hydrocephalus.
 - ii. Alzheimer disease.
 - iii. Wide spread frontal lobe tumors.

- iv. Binswanger disease.
- v. Pick disease.
- vi. Frontal lobe damage by trauma, stroke, or rupture
anterior communicating aneurysm.

6- **Sensory ataxia:** High stepping or stamping gait due to loss of position test in the legs. The patient walks with a wide base, continuously looking at the ground, rising his feet high in the air and stamping them onto the ground. The gait is greatly accentuated with the eyes closed and the patient has positive Romberg's sign. This sign tests the loss of position sense in the legs and it is not a test of cerebellar function. It is done by asking the patient to stand with his feet close together, and, if he can do this, he is then asked to close his eyes. If Romberg's sign is present as soon as his eyes are closed he begins to sway about or he may even fall. Causes of sensory ataxia include:

- i. Tabes dorsalis.
- ii. Subacute combined degeneration of the cord.
- iii. Friedreich's ataxia.

7- **A high stepping gait:** The foot is lifted high in the air in order to avoid tripping from the toes catching the ground. Unlike sensory ataxia, the gait is not broad based, nor is it accentuated with the eyes closed. It occurs when there is weakness of the extensor muscles of the feet. Causes include:

- i. Peroneal nerve palsy.
- ii. Peripheral neuropathy (alcoholics)
- iii. Progressive muscular atrophy.

8- **Waddling gait (Duck-like):** The feet are planted wide apart, the body is tilted backwards and sways from side to side as each step is taken. The gait disorder is due to difficulty in maintaining Truncal and pelvic posture because of proximal muscle weakness. Important Causes of waddling gait include the following:

- i. Congenital dislocation of the hips.
- ii. Proximal myopathies.

- iii. Duchenne muscular dystrophy.

9-Dystonic gait: usually the pathology lies in the basal ganglia.

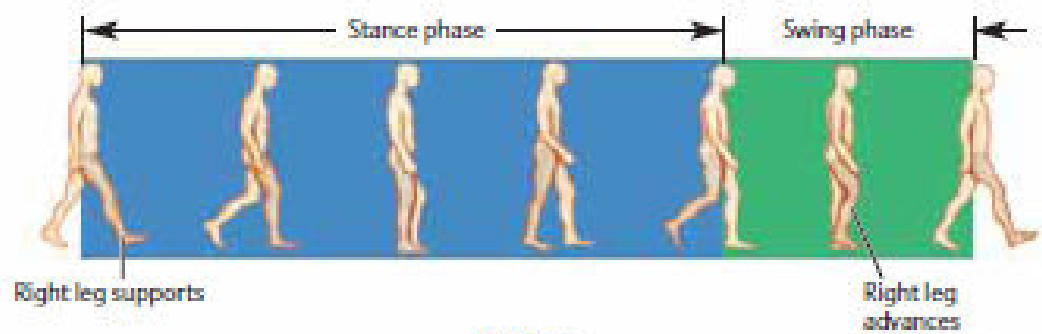
Causes include:

- i. Torsion dystonia
- ii. Dopa responsive dystonia
- iii. Paroxysmal dystonia
- iv. Huntington disease

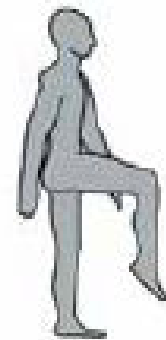
10-Toe- walking: Causes include:

- i. Progressive supranuclear palsy
- ii. Foot deformity
- iii. Cerebral palsy
- iv. Duchenne muscular atrophy
- v. Habit

11-Psychogenic or functional gait: Usually occurs in patients complaining of mental illness or some time due to a malingering state. Neurological examination is almost always normal and psychiatric consultation is advisable in certain patients.



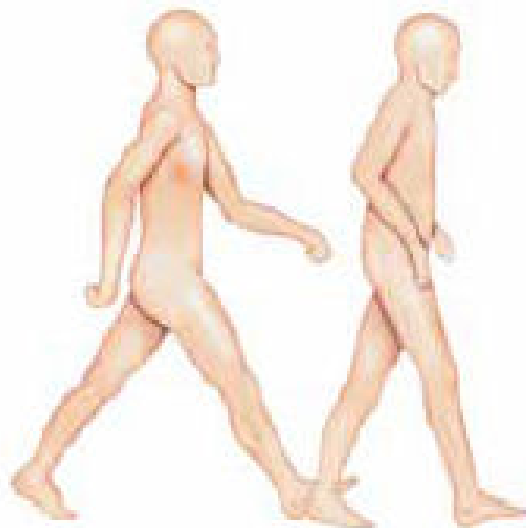Gait cycle



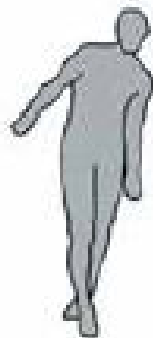Steppage gait



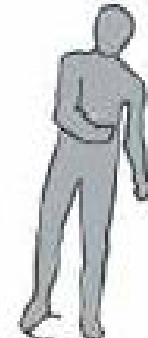Knee instability
(quadriceps paresis, leg dorsally angulated)



Posture and gait in youth (left) and old age (right)



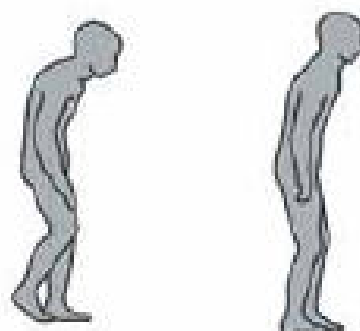
Ataxic gait



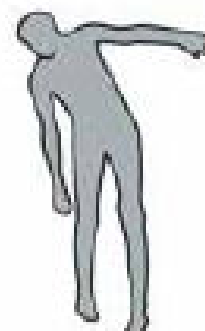
Spastic gait
(right hemiparesis)



Spastic gait
(spastic paraparesis)



Hypokinetic-rigid gait
(left, Parkinson disease; right, start delay/gait apraxia)



Psychogenic gait disturbances
(histrionic movements)

CHAPTER FOUR

CLINICAL LOCALIZATION OF NEUROLOGICAL WEAKNESS

Introduction

The findings on examination should indicate whether the weakness is due to an upper or lower motor neuron lesion, disorder of neuromuscular transmission, or a primary muscle disorder. In the case of upper or lower motor neuron disturbances, the clinical findings may also help to localize the lesion more precisely to a single level of the nervous system. Such localization helps to reduce the number of diagnostic possibilities.

4-1 Upper motor neuron lesions

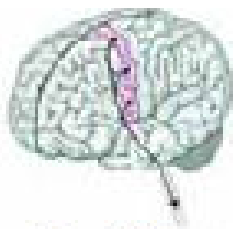
A. Signs:

- 1- Weakness or paralysis.
- 2- Spasticity.
- 3- Increased tendon reflexes.
- 4- An extensor plantar (Babinski) response.
- 5- Loss of superficial abdominal reflexes.
- 6- Little, if any, muscle atrophy.

B. Localization of the underlying lesion:

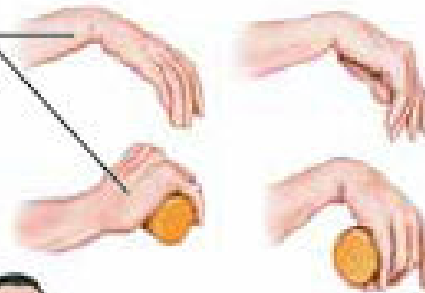- 1- A parasagittal intracranial lesion produces an upper motor neuron deficit that characteristically affects both legs and may later involve the arm.
- 2- A discrete lesion of the cerebral cortex or its projections may produce a focal motor deficit involving, for example, the contralateral hand. Weakness may be restricted to the contralateral leg in patient with anterior cerebral artery occlusion, or the contralateral face and arm, if the middle cerebral artery is involved. A more extensive cortical or subcortical lesion will produce weakness or paralysis of the contralateral face, arm and leg and may be accompanied by aphasia, visual field defect, or loss of discriminative sensation. The occurrence of seizure also suggests a cortical location of the lesion.

- 3- A lesion at the level of the internal capsule, where the descending fibers from the cerebral cortex are closely packed, commonly results in a severe hemiparesis that involves the contralateral limbs and face. See pictures at page 163.
- 4- A brainstem lesion commonly leads to bilateral motor deficits, often with accompanying sensory and cranial nerves disturbances, and ataxia. A more limited lesion involving the brainstem characteristically leads to a cranial nerve disturbance on the ipsilateral side and a contralateral hemiparesis, the cranial nerves affected depend on the level at which the brainstem is involved. Look to the picture below.
- 5- 5-A unilateral spinal cord lesion above the fifth cervical segment (C5) causes an ipsilateral hemiparesis that spares the face and cranial nerves. Lesion between C5 and the first thoracic segment (T1) affect the ipsilateral arm to a variable extent as well as the ipsilateral leg. A lesion below T1 will affect only the ipsilateral leg. Because, in practice, both sides of the cord are commonly involved, quadriparesis, or paraparesis usually results. If there is extensive but unilateral cord lesion, the motor deficit is accompanied by ipsilateral impairment of vibration and position sense and by contralateral loss of pain and temperature appreciation (Brown-Sequard syndrome). With compressive and other focal lesions that involve the anterior horn cells in addition to the fiber tracts traversing the cord, the muscles innervated by the affected cord segment weaken and atrophy. Therefore, a focal lower motor neuron deficit exists at the level of the lesion and an upper motor neuron deficit exists below it, in addition to any associated sensory disturbances.

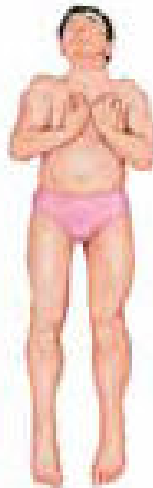

Pyramidal tract

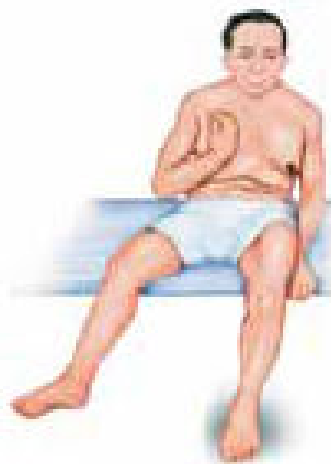Central monoparesis
(grasp induces contraction of antagonist muscles)



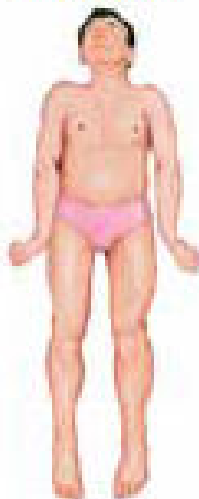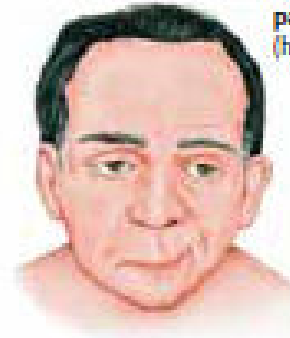
Peripheral paresis
(hand drop)



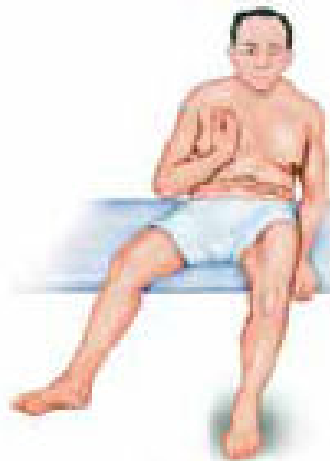Decortication



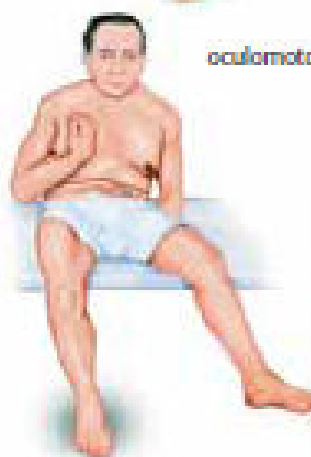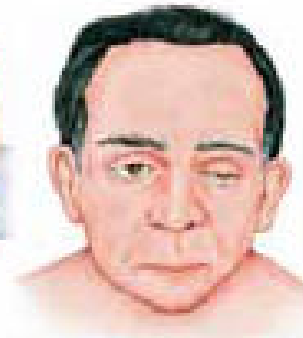Right hemiparesis
(lesion of internal capsule)



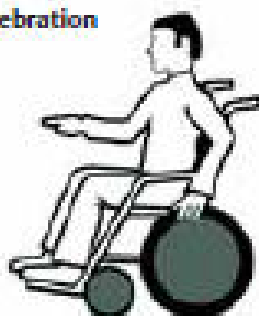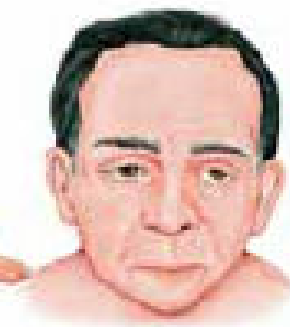Decerebration



Crossed paresis
(left midbrain lesion causing left oculomotor nerve palsy and right hemiparesis)



Crossed paresis
(lesion at the level of the pyramidal decussation causing paresis of right arm and left leg)



Spastic paraparesis
(parasagittal cortical syndrome)

4-2 Lower Motor Neuron Lesions

A. Signs:

- a. Weakness or paralysis.
- b. Wasting and fasciculation of the involved muscles.
- c. Hypotonia (flaccidity).
- d. Loss of tendon reflexes when neurons subserving them are affected.
- e. Normal abdominal and plantar reflexes-unless the neurons subserving them are directly involved, in which case reflex responses are lost.

B. Localization of the underlying lesion:

In distinguishing weakness from a root, plexus, or peripheral nerve lesion, the distribution of the motor deficit is of particular importance. Only those muscles supplied wholly or partly by the involved structure are weak Table (20, 21). The distribution of any accompanying sensory deficit similarly reflect the location of the underlying lesion Table (18, 19). It may be impossible to distinguish a radicular (root) lesion from discrete local involvement of the spinal cord. In the latter situation, however, there is more often a bilateral motor deficit at the level of the lesion, a corticospinal or sensory deficit below it, or disturbance of the bladder, bowel, or sexual function. Certain disorders selectively affect the anterior horn cells of the spinal cord diffusely, or the motor nerves, the extensive lower motor neuron deficit without sensory or autonomic changes help to indicate the site and nature of the pathologic involvement. Table 22 lists the causes of neuropathy according to the pattern of nerve fiber involvement.

Table 20. Innervations of selected muscles of the upper limbs

Muscles	Main root	Peripheral nerve	Main action
Supraspinatus	C5	Suprascapular	Abduction of the arm
Infraspinatus	C5	Suprascapular	External rotation of the arm at shoulder
Deltoid	C5	Circumflex	Abduction of the arm
Biceps	C5,6	Musculocutaneous	Elbow flexion
Brachioradialis	C5, 6	Radial	Elbow flexion
Extensor carpi radialis longus	C6,7	Radial	Wrist extension
Flexor carpi radialis	C6,7	Median	Wrist flexion
Extensor carpi ulnaris	C7	Radial	Wrist extension
Extensor digitorum	C7	Radial	Finger extension
Triceps	C8	Radial	Extension of the elbow
Flexor carpi ulnaris	C8	Ulnar	Wrist flexion
Abductor pollicis brevis	T1	Median	Abduction of the thumb
Opponens pollicis	T1	Median	Opposition of thumb
First dorsal interosseous	T1	Ulnar	Abduction of the index finger
Abductor digiti minimi	T1	Ulnar	Abduction of the little finger.

Table 21. Innervations of selected muscles of the lower limbs

Muscles	Main root	Peripheral nerve	Main action
Iliopsoas	L2,3	Femoral	Hip flexion
Quadriceps femoris	L3,4	Femoral	Knee extension
Adductors	L2,3,4	Obturator	Adduction of thigh
Gluteus maximus	L5, S1,2	Inferior gluteal	Hip extension
Gluteus medius and minimus	L4,5, S1	Superior gluteal	Hip abduction
Hamstrings	L5, S1	Sciatic	Knee flexion
Tibialis anterior	L4,5	Peroneal	Dorsiflexion of ankle
Extensor digitorum longus	L5, S1	Peroneal	Dorsiflexion of toes
Extensor digitorum brevis	S1	Peroneal	Dorsiflexion of toes
Peronei	L5, S1	Peroneal	Eversion of foot
Tibialis posterior	L4	Tibial	Inversion of foot
Gastrocnemius	S1,2	Tibial	Plantar flexion of ankle
Soleus	S1,2	Tibial	Plantar flexion of ankle

Table 22. The causes of lower motor neuron lesions according to the pattern of fiber involvement.

Predominantly symmetrical motor deficits	ALS, MMN, GBS, CIDP, acute porphyria, hereditary sensory motor neuropathy
Predominantly asymmetrical motor deficits	Neuropathy, ALS, poliomyelitis, spinal muscular atrophy, radicular lesion, plexus lesion, mononeuritis multiplex, mononeuropathy
Predominantly autonomic disturbances	DM, amyloidosis, GBS, vincristine therapy, porphyria, HIV, thallium poisoning, fabry disease, cryptogenic.
Predominantly sensory neuropathy	DM, alcohol, ethambutol, B12 deficiency, folic acid deficiency, metronidazole, phenytoin, thalidomide, leprosy, cytostatic agent e.g. vincristine, vinbastine, cisplatin, amyloidosis, HSN, monoclonal gammopathy, tabes dorsalis, friedreich ataxia, paraneoplastic, pyridoxine over dosage,
Large fiber sensory ataxic neuropathy	Sjogren's syndrome, B12 neuropathy, cisplatin neuropathy, pyridoxine neuropathy, friedreich's ataxia

ALS=amyotrophic lateral sclerosis, MMN=multifocal motor neuropathy, GBS=Gillain Baree syndrome, HSN= hereditary sensory neuropathy

4-3: Disorders of Neuromuscular Transmission:

A. Signs:

- Normal or reduced muscle tone.

- Normal or depressed tendon or superficial reflexes.
- No sensory changes.
- No long tract signs.
- Weakness, often patchy in distribution, not conforming to the distribution of any single anatomic structure, frequently involves the cranial muscles and fluctuate in severity (diurnal changes) over short period, particularly in relation to activity.

B. Localization of the underlying lesion:

Pathologic involvement of either the presynaptic or postsynaptic portion of the neuromuscular junction may impair neuromuscular transmission e.g. of presynaptic block includes myasthenic syndrome, botulism, and aminoglycoside antibiotics. Postsynaptic block typically occurs in myasthenia gravis. Differentiation between these disorders is not difficult depending on the history, physical examination, distribution of the affected muscles, relation to activities, underlying systemic disorders and certain ancillary investigations.

4-4 Myopathic Disorders:

A. Signs:

- Weakness, usually most marked proximally rather than distally.
- No muscle wasting or depression of tendon reflexes until at least an advanced stage of the disorder.
- Normal abdominal and plantar reflexes.
- No sensory loss or sphincter disturbances.
- No long tract signs.

B. Differentiation:

In distinguishing the various myopathic disorders, it is important to determine whether there is a family history of similar disease, whether the weakness is congenital or acquired, and whether there is any clinical evidence that a systemic disease may be responsible. The distribution of the affected muscles is often especially important in distinguishing the various hereditary myopathies.

CHAPTER FIVE

EXAMINATION OF UNCONSCIOUS PATIENT

5-1: Coma: It is a sleep like state from which the patient can not be aroused. The eyes are typically closed and do not open spontaneously. The patient does not speak, and there is no purposeful movement of the limbs. Verbal stimulation produce no response. Painful stimulation may produce no response or may produce non purposeful reflex movements mediated through the spinal cord or brainstem pathways. Coma results from disturbances in the function of either the brainstem reticular activating system above the midpons or both cerebral hemispheres, since these are the brain regions that maintain consciousness.

5-2: The Purpose of Examination:

- 1- To determine the state or the level of consciousness.
- 2- To identify or exclude systemic diseases known to cause disturbances of consciousness.
- 3- Localization of the lesion whether it is supratentorial, infratentorial, or metabolic.

5-3: Methods of Examination:

5-3-1 General physical examination:

A. Signs of trauma:

i. Inspection of the head may reveal signs of basilar skull fracture, including the followings:

- 1- Raccoon eyes---periorbital ecchymosis.
- 2- Battle's sign---swelling and discoloration overlying the mastoid bone behind the ear.
- 3- Hemotympanum---blood behind the tympanic membrane.
- 4- Cerebrospinal fluid rhinorrhea or otorrhea: Leakage of the CSF from the nose or ear. CSF rhinorrhea must be distinguished from other causes of rhinorrhea, such as allergic rhinitis. It has been suggested that CSF can be distinguished from nasal mucus by the higher glucose content of the CSF,

but this is not always the case. The chloride level may be more useful, since CSF chloride concentration are 15-20 mEq/higher than those in mucus.

ii. Palpation of the head may demonstrate a depressed skull fracture or swelling of the soft tissues at the site of trauma.

B. Color and condition of the skin: The following remarks are important in coma:

- i. Pallor: It may occur in syncope, severe blood loss and hypoglycemia.
- ii. Polycythemic face: It is seen in hypertension, alcoholism and sometimes in cerebral hemorrhage.
- iii. Cyanosis of the face and neck: It accompanies respiratory obstruction, epilepsy, and some intracranial vascular accidents. It is, of course, a crucial sign requiring correction as a matter of emergency if possible, and should, therefore, until proven otherwise, be assumed to be due to respiratory obstruction.
- iv. Cyanosis of the limbs: It is seen in peripheral circulatory stagnation, severe coma and collapse.
- v. Jaundice: It may suggest multiple metastases, but may also indicate hepatic coma due to either primary liver disease or drug toxicity.
- vi. A cherry red color: It is seen in carbon monoxide poisoning.
- vii. Petechiae and ecchymosis: These are found after fit, in bacterial endocarditis, severe septicemia, collagenosis, blood dyscrasias, and in patients on high steroid dosage.
- viii. Corrosion of mouth and lips: This indicates poisoning.

C. The ears: It should be examined carefully for signs of:

- i. Middle ear infection, which may indicate an intracranial abscess.
- ii. Tenderness and swelling over the mastoid, for the same reason as above.

D. The tongue: A common cause of coma being epilepsy, the tongue should be examined for evidence of having been bitten. The surface and the

inside of the cheek, palate, fauces, and pharynx should be inspected for the effect of corrosive fluids.

- E. **Blood pressure:** Elevation of blood pressure in a comatose patient may reflect long standing hypertension, which predisposes to intracranial hemorrhage, encephalopathy or stroke. Elevation of blood pressure may also be a consequence of the process causing the coma, as in intracerebral or subarachnoid hemorrhage. Hypotension can occur in coma caused by alcohol intoxication, barbiturate intoxication, diabetes, and other causes.
- F. **Temperature:** Coma with hyperthermia is seen in heat stroke, status epilepticus, malignant hyperthermia, anticholinergic drug intoxication, pontine hemorrhage and certain hypothalamic lesions. Hypothermia can occur in coma caused by ethanol or sedative drugs intoxication, hypoglycemia, Wernicke's encephalopathy and myxoedema.
- G. **Pulse:** The state of pulse may give a hint about the cause of coma, the followings are important remarks:
- i. Rapid and weak as in shock.
 - ii. Slow and weak as in vasovagal attacks.
 - iii. Very slow and full as in complete heart block (When Stokes-Adams attacks occur), and in markedly increased intracranial pressure.
 - iv. Weak and irregular as in low brainstem lesions.
- H. **Respiration and pattern of breathing:** Examination of respiration is of utmost importance because any respiratory obstruction is a life threatening and must be corrected immediately by any means without any delay. In addition, certain patterns of breathing may be of localizing value in coma, the following patterns are worthy to be mentioned :
- i. Cheyne - Stokes respiration (CSR), in which there is alternating hyperpnoea and apnea. This usually indicates bilateral cerebral or high brainstem lesion or metabolic derangement. The causal lesion is rarely as low as the upper pons. It is not a grave sign by itself but

when it gives way to other abnormal respiratory pattern which implicate the brainstem, then it is a grave sign.

- ii. Central neurogenic hyperventilation: This disorder characterized by rapid and deep breathing to the extent of alkalosis. It occurs in lesions of the lower midbrain-upper pontine tegmentum, either primary or secondary to tentorial herniation. In addition, this type of breathing occurs in metabolic acidosis like diabetic ketoacidosis or uremia.
- iii. Apneustic breathing: A pause of 2-3 seconds in full respiration, or so called short cycle CSR, in which a few rapid deep breaths alternate with apneic cycles. It occurs in low pontine lesions usually due to basilar artery occlusion.
- iv. Ataxic breathing: The rhythm of breathing is chaotic, being irregularly interrupted, each breath vary in rate and depth. It occurs with lesions of the dorsomedial part of the medulla.
- v. Gasping: Very irregular, slow, deep, gasping respirations, sometimes associated with hiccups, suggest terminal medullary failure.

5-3-2 Systemic examination:

This part of examination must be done in the conventional way. It is very important because it may discover the etiology and explain this coma state.

The followings are examples:

1- Cardiovascular system:

- i. Mitral stenosis and atrial fibrillation, which may raise the possibility of cerebral embolism.
- ii. Endocarditis, which also raise the possibility of subarachnoid hemorrhage or cerebral abscess.
- iii. Cardiomyopathy---cerebral embolism---coma.

2- Respiratory system:

- i. Bronchiectasis----septic embolism---cerebral abscess---coma.
- ii. Bronchogenic carcinoma---brain metastasis.
- iii. Respiratory failure---pulmonary encephalopathy.

3- Abdominal examination:

- i. Lymphoproliferative disorders---brain metastasis.
- ii. Myeloproliferative disorders---brain metastasis, intracranial hemorrhage, stroke, etc.
- iii. Infectious causes---meningitis, encephalitis.
- iv. Ascitis---hepatic encephalopathy, cerebral tuberculosis, cerebral metastasis, according to the cause of ascitis which may be cirrhosis, malignancy, or tuberculous process.
- v. Polycystic kidney---subarachnoid hemorrhage.
- vi. Renal failure---myoclonic epilepsy, dialysis disequilibrium syndrome, metabolic coma.

4- Locomotor system:

- i. Systemic lupus erythematosus----epilepsy, stroke, drug toxicity.

5-3-3 Neurological examination:

Neurological examination is designed to give a localization of different lesions causing coma. It is directed to answer whether the lesion is structural or diffuse (metabolic), and if it is structural, whether it is supratentorial or infratentorial. In addition to the observation of the pattern of respiration, the following steps are the most useful in this respect:

- 1- The level of consciousness.
- 2- Signs of meningeal irritation.
- 3- Neuro-ophthalmological examination.
 - i. Fundi.
 - ii. Pupils.
 - iii. Eye movements.
- 4- The motor system:
 - i. Inspection.
 - ii. Tone.
 - iii. Reflexes.

iv. Response to pain.

1- The level of consciousness:

It is important to note exactly the degree of responsiveness to external stimuli which include:

- a. Verbal stimulation-----calling the patient's first name, a sudden loud noise, etc.
- b. Tactile stimulation---By gentle touching.
- c. Painful stimulation---Sternal pressure by hard object or supra-orbital pressure by the examiners thumb.

The responses of the patient to these stimuli are calculated according to Glasgow Coma Scale see Table (1). Examination of the unconscious patient should be directed toward defining the level of consciousness, and any change from hour to hour. Change in the level of consciousness is the single most important piece of information which will indicate the need for a change of the management.

2- Signs of meningeal irritation

- a. Neck stiffness: It is done by first moving the neck to both sides (lateral movements) and the examiner then passively flexes the patient neck. Normally, the chin should touch the chest. Positive neck stiffness means resistance to passive flexion of the neck due to spasms of the extensor muscles of the neck. Rigidity means limitation of neck movements to all directions.
- b. Kernig's sign: It is tested with the patient supine in the bed, by passively extending patient's leg, when his hip and knee are fully flexed. Positive Kernig's means resistance to passive extension of the leg due to spasm of the hamstring muscles. It is a less sensitive than neck stiffness.
- c. Brudzinski's sign: With the patient supine in the bed, and the examiner hand on the patient's chest, passive neck flexion results in flexion at the hip which is often asymmetrical.

These tests depend upon the fact that stretching the spinal cord nerve roots in meningeal irritation causes reflex muscular spasm in the paraspinal and sacral

muscles. They are of great importance in leading to the prompt diagnosis of meningitis or subarchnoid hemorrhage, but they are usually lost in deep coma and extremes of age. In some patients with raised intracranial pressure, in which herniation of the cerebellar tonsils into the foramen magnum has occurred, neck stiffness may also be present but Kernig's sign is usually negative in this situation.

3- Fundi

Examination of the optic fundi may reveal papilledema or retinal hemorrhages, compatible with acute or chronic hypertension or an elevated intracranial pressure. Papilledema develops within 12 hours in cases of brain trauma or hemorrhage, but, if pronounced, it usually signifies brain tumor or abscess, i.e. a lesion of longer duration. Subhyaloid (superficial retinal) hemorrhages in an adult strongly suggest subarachnoid hemorrhage.

4- Pupils

- i. Normal pupil. Normal pupils are 3-4 mm in diameter, and equal bilaterally. They constrict briskly and symmetrically to light.
- ii. Thalamic pupil: They are slightly smaller than normal, reactive to light and present in the early stages of thalamic compression from a mass lesion.
- iii. Fixed dilated pupils. They are greater than 7 mm in diameter and non reactive to light. Usually result from compression of the oculomotor (III) cranial nerve any where along its course from the midbrain up to the orbit, but May also seen in anticholinergic or sympathomimetic drug intoxication. The most common cause of fixed dilated pupil in a comatose patient is transtentorial herniation of the medial temporal lobe from a supra-tentorial mass.
- iv. Fixed midsize pupils. Pupils fixed at about 5 mm (4-7 mm), usually as a result of midbrain lesion, whether due to primary lesion or secondary to central pressure herniation. Atropine use by previous examiners must also be excluded before a diagnosis of midbrain lesion is made.

- v. Pinpoint pupil (0.5-1.5 mm). In a comatose patient it usually indicates opioid overdose or focal damage at the pontine level. Under these conditions, the pupils may appear unreactive to light except, perhaps with a magnifying glass. Pinpoint pupils are also caused by organophosphorus poisoning, miotic eye drops, or neurosyphilis.
- vi. Unilateral pupillary dilatation. With deteriorating level of consciousness it should be considered as a sign of unilateral tentorial herniation until proved otherwise. It is commonly but not invariably, on the side of the expanding lesion and demands prompt surgical action.

N.B.: In most cases of toxic or metabolic coma, the pupillary light reflexes are spared; their presence or absence is, in fact, the single most important sign in distinguishing metabolic from structural disease.

5- Eye movements (extraocular muscle movements)

- i. **Pathways tested:** The neural pathways to be tested begin at the pontomedullary junction (vestibular nerve and nucleus), synapses in the pons (horizontal gaze center and abducent (VI) nerve nucleus), ascend through (the medial longitudinal fascicule) and arrive at the midbrain level (oculomotor -III- nucleus) and nerve..
- ii. **Methods of testing:** In the absence of voluntary eye movements, the assessment of ocular motility in comatose patients relies heavily on reflex eye movement, including the oculocephalic reflex (dolls-eye maneuver), and the oculovestibular reflex (cold water caloric testing). Caloric testing provides a stronger stimulus than the oculocephalic reflex.
- iii. **Full range-movements:** A comatose patient without brainstem disease will often demonstrate full conjugate horizontal and vertical eye movements during dolls eye maneuver and always exhibit tonic conjugate movement of both eyes to the side of the ice water irrigation during the caloric testing. Irrigation of both ears with cold water induces downward deviation of the eyes, warm water induces upward deviation.

iv. Abnormalities of the lateral gaze

Conjugate gaze palsy

When both eyes remain deviated toward the same side in a comatose patient, the lesion may be in the cerebral hemisphere or in the pontine tegmentum.

- a. In hemispheric lesion. The eyes look towards the side of the lesion i.e. away from hemiparetic side, but can be brought to the other side with the oculocephalic maneuver, caloric testing or both.
- b. In unilateral pontine lesion. The eyes look toward the hemiparetic side, but neither the oculocephalic, nor the caloric testing overcome pontine gaze palsy.

Disconjugate gaze palsy

Isolated failure of ocular adduction in the absence of pupillary abnormality and with normal vertical eye movement (elicited by oculocephalic or oculovestibular reflexes) indicates a lesion of the medial longitudinal fasciculus (MLF) in the upper pons ipsilateral to the eye that fail to adduct. MLF involvement is commonly bilateral in comatose patients. Rarely, metabolic coma (such as that due to barbiturates, amitrytline, or hepatic coma) may induce a transient MLF syndrome that can usually be overcome by vigorous caloric testing

Abnormalities of vertical gaze

- I- Disconjugate vertical gaze in the resting position (skew deviation) indicates the following possibilities:
 - 1- Brachium pontis or dorso-lateral medulla lesion, on the side of the depressed eye.
 - 2- MLF lesion, on the side of the elevated eye.
- II- Conjugate deviation of the eyes below the horizontal meridian, indicate a structural lesion that affect the tectum of midbrain but is occasionally caused by metabolic encephalopathy.

III- Upward gaze palsy (elicited by reflex eye movement) is usually present with bilateral midbrain tectal damage.

IV- Downward gaze palsy: It occurs in bilateral lesion of the midbrain tectum (peri-rubral region)

6-The motor system

A- **Inspection:** This applies particularly to the abnormal posture and abnormal movement of the body and the limbs.

Abnormal postures of importance in states of disturbed consciousness

The important abnormal postures that are of localizing value in comatose patient are the followings:

- 1- Neck retraction: It usually indicates meningeal irritation, but it may occur in cerebellar tonsillar conning.
- 2- Opisthotonus: This is not uncommon in small children with meningeal irritation, or advanced degenerative lesions. In adults, it may occur in tetanus and severe meningeal irritation.
- 3- Acute hemiplegia: The patient lies with the head dropped to one side, one upper limb pronated and adducted, and one lower limb extremely rotated.
- 4- Decerebrate posture: All the limbs are extended, the upper limbs are pronated and the feet are plantar flexed. It occurs in lesions of the midbrain between the superior colliculus and pons. Metabolic disorders can produce this posture, so it must be excluded before a diagnosis of structural damage to the motor pathway had been made.
- 5- Decorticate posture: The upper limbs are flexed and the lower limbs are extended. It is seen in extensive lesions at the level of the basal nuclei, or between this level and cortex. It is also frequently seen in metabolic disorders.

Abnormal movements of importance in states of disturbed consciousness

- 1- Convulsions: Coma accompanies and follows isolated fits or status epilepticus, of idiopathic or symptomatic origin.

2- Attacks of generalized rigidity and decerebrate attacks: These may occur when the brainstem is the site of the primary disease, when it is under compression, subjected to trauma, or has had hemorrhage into its substance either primarily or as a result of tentorial herniation.

3-Rigors and tremors:

Intermittent rigors without rise in temperature occur when there is irritative lesion of the ventricular wall e.g. by rupture of an abscess or hematoma, and coarse tremor of the hands and arms may accompany this lesion.

B- Tone

The tone of the limbs can be tested in the conventional way, but remember that in the acute stage of a severe intracranial lesion, the tone may be lost (spinal shock), rather than being increased, on the side opposite to the lesion.

Raise both arms together and let them fall back, normally, this fall is checked and slowed, but in unilateral paralysis the arm will fall unchecked like a dead object. Next raise the legs into the flexed position, so that the soles of the feet rest on the bed, and then allow them to fall back. Unparalyzed limb will remain in that position or slowly extended. A paralyzed limb will rapidly fall back to its original position.

N.B.: Asymmetry of tone is more significant in comatose patients, rather than bilateral increase or decrease.

C- The reflexes:

Testing the reflexes, being an objective procedure, can be carried out in the normal way and the usual interpretation can be obtained, but in states of deep coma, the interpretation of the results may be difficult.

Tendon reflexes may be absent on the paralyzed side, or bilaterally absent in the deep coma. The planter responses may be absent, or bilaterally extensor, and so have little localizing value, except when there is a unilateral extensor planter which may indicate the side of a pyramidal system lesion.

D- Motor responses to pain

The motor response to pain is tested by applying strong pressure on the supraorbital ridge, sternum, or nail beds. The response to such stimuli may be helpful in localizing the level of cerebral dysfunction in comatose patients or providing a guide to the depth of coma.

- 1- With cerebral dysfunction of only moderate severity, patients may localize the offending stimulus by reaching toward the site of stimulation.
- 2- A decorticate response to pain is classically associated with lesions that involve the thalamus directly or large hemispheric masses that compress it from herniation.
- 3- A decerebrate response: Tends to occur when midbrain function is compromised. Decerebrate posturing generally implies more severe brain dysfunction than decorticate posturing, but neither response localizes the site of disease exactly.
- 4- Bilateral symmetric posturing may be seen in both structural and metabolic disorders.
- 5- Unilateral or asymmetric posturing suggests structural disease in the contralateral hemisphere or brainstem.
- 6- In patients with pontine and medullary lesions, there is usually no response to pain, but occasionally some flexion at the knee is noted (A spinal reflex).

5-4 Results of Examination

The most important step in evaluating the comatose patient is to decide whether unconsciousness is the result of a structural brain lesion (for which emergency neurosurgical intervention may be critical) or diffuse encephalopathy caused by metabolic disturbance, meningitis, or seizures (for which surgical procedures are unnecessary and medical treatment may be required). The most common diagnostic dilemma is to try to differentiate between supratentorial (hemispheric) mass lesion and metabolic encephalopathy.

5-4-1:Supratentorial structural lesion:

Supratentorial structural lesions cause coma by 2 ways:

A-Bilateral hemispheric lesions: The best example of such lesions is bilateral hemispheric infarction or bilateral thalamic infarctions. The presentation of these lesions resembles in many aspects the presentation of metabolic disorders; however, cerebral infarctions even when being bilateral can be recognized by the following features:

- 1- Appear more abruptly than metabolic encephalopathies.
- 2- Cause asymmetrical motor signs, at least early in their course.

B-Unilateral hemispheric lesion with secondary tentorial herniation: The above lesion impairs consciousness either by compressing the diencephalic or upper brainstem structures. Prime examples are hemispheric tumors and subdural or intracerebral hemorrhage. Massive infarction may evolve in a similar manner. Depending on the supratentorial location of the mass and the size of the tentorial opening, either one of two different clinical syndromes may result, lateral herniation or central herniation:

- I- Lateral herniation: it occurs in a patient with a wide tentorial opening. The lateral extracerebral or temporal lobe masses push the mesial temporal lobe between the ipsilateral aspect of the midbrain and the free edge of the tentorium. The following events occur in consequences:
- 1- Ipsilateral dilated pupil due to compression of the ipsilateral third cranial nerve. Recovery is possible at this stage.
 - 2- Hemorrhagic infarction of the medial occipital lobe due to compression of the posterior cerebral artery at the tentorial edge.
 - 3- Ipsilateral hemiparesis due to compression of the contralateral cerebral peduncle against the contralateral tentorial edge.
 - 4- Midbrain infarction and hemorrhage due to tearing of the paramedian perforating vessels that feed the midbrain tegmentum. Recovery is impossible at this stage.

- 5- Mid-size pupils: This appears first in the eye originally involved, and shortly afterward in the other eye. This occurs due to involvement of the sympathetic pathway in the midbrain.
- 6- Impairment of ocular movements: This appears first in the eye originally involved, and later on in the other eye. Abduction may remain as the only elicitable eye movement.

II- Central herniation: Unlike the temporal masses, frontal, parietal, and occipital masses first compress the diencephalon which as the supratentorial pressure increases shift downward and buckles over the midbrain. Subsequently flattening of the midbrain in the rostro-caudal direction causes elongation and rupture of the paramedian perforating arteries feeding these structures, resulting in infarction and hemorrhages in the tegmentum of the midbrain (first) and pons (afterward). The characteristic evolution of the clinical picture has been termed the central syndrome of rostro-caudal deterioration. Description of this syndrome enables us to review the characteristic clinical findings with lesions at the different levels of the brainstem.

Early Diencephalic stage

- 1- Pattern of breathing: Normal but is punctuated by deep sighs and yawns.
- 2- Pupils: Small (about 2 mm in diameter) and reactive to light.
- 3- Reflex eye movement: Attempt to perform the doll's eye maneuver may provide enough stimulus to awaken the patient, and quick eye movement (saccades) are then elicited rather than the slow adversive movements of the oculocephalic reflex. For this reason, caloric stimulation may induce nystagmus.
- 4- Motor response to pain: Purposeful or semi-purposeful (localizing) and often asymmetric.

Late diencephalic stage

- 1- Pattern of breathing: Cheyne-Stokes
- 2- Pupils: Small and reactive

- 3- Reflex eye movements: Elicits full conjugate deviation of the eyes
- 4- Motor response to pain: Decorticate posturing which may be also asymmetric.

Midbrain stage

- 1- Pattern of breathing: deep and rapid
- 2- Pupils: Mid-sized (about 5 mm in diameter), fixed, irregular and eccentric.
- 3- Reflex eye movements: restricted or no vertical eye movement, bilateral failure of adduction.
- 4- Motor response to pain: elicits decerebrate (extensor) posturing.

Pontine stage

- 1- Pattern of breathing: Quick and shallow
- 2- Pupils: Fixed, mid-sized.
- 3- Reflex eye movement: Loss of both abduction and adduction. Eye movements are now unobtainable.
- 4- Motor response to pain: No motor response or only leg flexion

Medullary stage

In this stage, ataxic breathing soon gives way to apnea. The blood pressure drops, and the pulse becomes irregular. Other features are the same as the pontine stage.

False localizing signs

Supratentorial masses in the temporal or frontal lobes that are clinically silent and midline lesions like hydrocephalus or subdural hematoma may fail to produce focal signs and instead they cause a rise in the intracranial pressure and consequently produce cranial nerve dysfunction that may be mistaken for evidence of posterior fossa lesion. The important false localizing signs are:

- 1- Sixth nerve palsy and papilledema (the commonest)
- 2- Other ophthalmoplegias
- 3- Unilateral or bilateral deafness
- 4- Facial palsy

5- 9th, 10th cranial nerve palsy

6- Hemiparesis ipsilateral to the lesion due to kernohan's notch.

5-4-2: Subtentorial structural lesions

1- Coma characteristics: sudden onset with focal brainstem signs, strongly support the diagnosis

2- Pupillary function and extraocular movements: these are the most helpful features of the neurological examination, especially if the abnormalities are asymmetric.

a- Pupil:

In midbrain lesions, they are mid-sized and non-reactive to light.

In pontine lesions: Pupils are pinpoint and non-reactive.

b- Extraocular movements: Conjugate gaze deviation away from the side of the lesion and toward the hemiparesis or disconjugate eye movement, such as internuclear ophthalmoplegia, strongly suggests subtentorial lesion. Impaired adduction with midbrain lesion, and impaired adduction and abduction with pontine lesion.

3- Motor responses to pain are generally not helpful in separating subtentorial from supratentorial lesions.

4- Ventilatory pattern: Ataxic and gasping ventilatory pattern are most commonly seen with ponto-medullary lesions. Other patterns are seen with metabolic disturbances and with structural lesions at a variety of sites in the brain. They are, therefore, not useful for anatomic localization of disorders causing coma.

5-4-3: Metabolic encephalopathy (diffuse encephalopathy)

1- Onset of coma is usually gradual

2- There are usually no focal signs such as hemiparesis, hemisensory loss or aphasia.

3- Asterixis, myoclonus, and tremor preceding coma are important clues that suggest metabolic disease.

- 4- The finding of reactive pupils in the presence of otherwise impaired brainstem function is the hallmark of metabolic encephalopathy. The few metabolic causes of coma that also impaired pupillary reflexes include glutethemide overdose, massive barbiturate overdose, acute anoxia, marked hypothermia and anticholinergic poisoning (large pupils), and opiate overdose (pinpoint pupils). Even in these conditions, however, completely non reactive pupils are uncommon.
- 5- Reflex eye movements: Usually normal, it can be impaired by sedative drugs or Wernicke's encephalopathy.
- 6- Motor responses: usually symmetric, but may be asymmetric with hypoglycemia, hyperosmolar non-ketotic hyperglycemia or hepatic encephalopathy.

CHAPTER SIX

CEREBRAL LOBES EXAMINATION

6-1 Frontal Lobe Examination

- 1- Test judgment and reasoning: Patients with unilateral lesion usually have slight elevation of mood, difficulty in adaptation and loss of initiative. Bilateral lesions (especially if pre-frontal parts are affected) lead to abulia (delay in all psychomotor responses), or akinetic mutism, lack of ability to sustain attention and solve complex problems, rigidity of thinking, behavioral disinhibition and labile mood.
- 2- Speech examination: Usually reveals expressive aphasia (dominant lobe lesion).
- 3- Praxias testing: Lip tongue apraxia, sympathetic apraxia of left hand (dominant lobe lesion).
- 4- Primitive reflexes examination: Usually released. If prefrontal areas are affected whether in unilateral or bilateral lesions.
- 5- Cranial nerves examination: Check for:
 - a- Unilateral anosmia: With involvement of orbital part such as with olfactory groove meningioma.
 - b- Optic atrophy: Involvement of orbital parts of frontal lobe, such as olfactory groove meningioma which may cause pressure on ipsilateral optic tract and olfactory tract.
 - c- Jaw jerk: Exaggerated jaw jerk is usually encountered in pseudobulbar palsy. The latter may be a manifestation of bifrontal disease.
- 6- Motor system examination: Unilateral frontal disease usually causes contralateral spastic hemiplegia, while bilateral frontal diseases usually cause bilateral spastic hemiplegia.
- 7- Gait examination: This may reveal
 - hemiplegic gait-----unilateral frontal disease
 - spastic paraplegic gait-----bilateral frontal disease

- apraxic gait-----sever bilateral frontal disease with affection of pre-frontal areas.

6-2 Temporal Lobe Examination

- 1- Test judgment and reasoning: Disease of either temporal lobe usually causes auditory, visual, olfactory, and gustatory hallucination. In addition, it may cause emotional and behavioral changes.
- 2- Test memory:
 - a- Impairment in test of verbal material presented through the auditory sense (poor verbal memory) ---dominant lobe lesion.
 - b- Impairment in tests of visually presented non-verbal material (poor non-verbal memory) ---non dominant temporal lobe lesion.
 - c- Korsakoff amnestic defect---bilateral hippocampal formation lesion.
- 3- Test speech: Detection of Wernicke's aphasia or amnestic aphasia indicate dominant temporal lobe lesion
- 4- Gnosis (integrative sensory function):
 - a- Visual agnosia ---dominant lobe lesion
 - b- Agnosia for sound and some music---non-dominant temporal lobe lesion.
- 5- Cranial nerves:
 - a- Second cranial nerve: superior quadrantic defect is the result of diseases of either temporal lobe.
 - b- Facial weakness

6-3 Parietal Lobe Examination

- 1- Test orientation:

Confusion ----non-dominant (right) parietal lobe lesion.
- 2- Examine speech: Alexia may be disclosed in dominant parietal lobe lesion.
- 3- Test for integrative sensory function: You may find the following disorders:

- Astereognosis, agraphesthesia, absence of 2 points discrimination, allesthesia and unilateral disorder of body scheme. These are observed more frequently with right than left parietal lobe lesions.
- Bilateral disorders of body scheme (Gertsmans syndrome), and tactile agnosia ----dominant parietal lobe lesion.

4- Test for integrative motor function:

- Bilateral ideomotor and ideational apraxia (dominant lobe)
- Dressing apraxia---non-dominant lobe lesion
- Constructional apraxia-----angular gyrus of either lobes.

5- Test cranial nerves:

- Visual field-inferior quadrantic field defect---right or left lobe lesion.
- Visual inattention--- lesion of either lobe (right or left).
- Abolition of optokinetic nystagmus with target moving toward the side of the lesion----lesion of either lobe.

6- Examine the motor system: Mild hemiparesis, unilateral muscular atrophy in children, hypotonia, and hemiataxia ---- lesion of either lobe.

6-4 Examination of the Occipital Lobe

1- Ask about visual illusions and visual hallucinations.

I) Visual illusions (metamorphopsias): Ask about any distortion of form, size, movement, or colors of seen object. These are more frequent with right sided than left sided lesions.

II) Visual hallucinations: It is of 2 types:

- Elementary (unformed) hallucinations: They indicate lesion of the primary visual area 17 of either lobe
- Complex (formed) hallucinations: They are indicative of lesion in the visual association areas of either lobe or their connections with the temporal regions.

2- Test for visual agnosias:

I) Visual object agnosia: It consists of a failure to name and indicate the use of a seen object by spoken or written words or by gesture. It is

usually associated with visual verbal agnosia (alexia) and homonymous hemianopia. Site of the lesion is usually bilateral occipital disease and sometimes encountered in pure left sided lesions.

II) Simultanagnosia: It means failure to perceive simultaneously all the elements of a scene and to properly interpret the scene. It is part of Balint syndrome. Site of the lesions is the dominant occipital area 18 or bilateral in the superior part of the occipital association cortices.

III) Balint syndrome: This consists of:

- i. Ocular apraxia: Faulty visual scanning.
- ii. Optic ataxia: faulty visual reaching of the target.
- iii. Visual inattention: Inability to perceive bilateral visual stimuli presented simultaneously to the patient. Site of the lesion is bilateral occipital disease.

IV) Prosopagnosia: The patient can not identify a familiar face by looking at the person. As a rule, other agnosias are present in such cases (color agnosia, simultanagnosia), and there may be topographic disorientation and constructional or dressing apraxia. Visual field defects are nearly always present. Site of the lesion is bilateral occipital disease.

V) Visual verbal agnosia: The patient loses the ability to read aloud, to understand written script, and often, to name colors (visual verbal color anomia). The patient also has right homonymous hemianopia. Site of the lesion is in the left visual cortex, left geniculocalcarine tract, and splenium of corpus callosum. So the visual information reach only the right occipital lobe, however, this information can not be transferred via the callosal pathways to the angular gyrus of the left (dominant) hemisphere.

VI) Topographagnosia (topographic memory loss): The patients are unable to orient themselves in an abstract spatial setting. Site of the lesion--right occipital lobe.

3- Examine the second cranial nerve: Check for:

- I- Cortical blindness: With bilateral lesions of the occipital lobes (destruction of area 17 of both hemispheres), there is loss of sight and a loss of reflex closure of the eyelids to bright light or threat. The pupillary light reflexes are preserved.
- II- Visual anosognosia (Anton syndrome) .The main characteristic of this syndrome is denial of blindness by a patient who obviously cannot see. Site of the lesion ----Striate cortex and plus the visual association areas.
- III- Homonymous hemianopia: usually results from a lesion of one occipital lobe. Other types of visual fields defects can results from occipital lobe lesion and this is off course related to the site of the lesion in the striate cortex.

CHAPTER SEVEN

AUTONOMIC NERVOUS SYSTEM EXAMINATION

7-1 Method of Examination

A-Tests reflecting parasympathetic damage.

1-Heart rate response to Valsalva maneuver

The test is performed by asking the patient to blow into a mouth- piece connected to an aneroid manometer and holding it at a pressure of 40 mm mercury for (15) second, while a continuous electrocardiogram (ECG) is recorded. The results are expressed as the valsalva ratio which is the ratio of the longest R-R interval after the maneuver reflecting the overshoot bradycardia to the shortest R-R interval during the maneuver reflecting the tachycardia during the strain. the mean of the three ratios is taken as a final result.

2-Heart rate(R-R interval) variation during deep breathing.

The patient sits quietly and breaths deeply at six breaths per minute (5 second in and 5 second out) for one minute , an ECG is recorded through out the period of deep breathing and with a marker used to indicate the onset of each inspiration and expiration .The maximum and minimum R-R interval during each breathing cycle are measured with a ruler and converted to beat / minute .The results then expressed as the mean of difference between maximum and minimum HR for the six measured cycle in beats/minute. Heart rate variation has also measured as the ratio of HR of expiration (E) to inspiration (I). E/I ratio.

3-Immediate HR response to standing 30:15 ratios

The test is performed with the patient lying on a couch while the HR is recorded continuously on ECG. The patient is then asked to standup unaided and the point at standing is marked on ECG. The shortest R-R at or around the 15th beat and the longest R-R at or around the 30th beat, after standing, is measured. This is expressed by the 30:15 ratios (R-R interval of the 30th to the R-R interval of the 15th.

B-Tests reflecting sympathetic damage.

1-Blood pressure response to standing.

The test is measured by measuring the patient blood pressure while he is lying down quietly and again when he stands up after three minutes. The postural fall in blood pressure is taken as the difference between systolic Bd-p lying and systolic blood pressure standing.

2-Blood pressure response to sustained handgrip.

The maximum voluntary contraction is first determined using a hand grip dynamometer. Hand grip is then maintained at 30% of that maximum as long as possible for up to five minutes .Blood pressure is measured three times before, and one minute interval during handgrip, the result is expressed as the difference between the highest diastolic blood pressure during handgrip and the mean of the three reading before handgrip begun.

7-2 Results of Autonomic Testing

The results of each of the five tests are classified into normal, borderline and abnormal according to Ewing scoring Table (23).

The results can be then categorized and usually falls into one of four groups

1-Normal

2-Early parasympathetic damage: with results of only one of the three tests of parasympathetic functions is abnormal.

3-Definite parasympathetic damage: with results of at least two of the tests of the parasympathetic functions is abnormal.

4-Compined parasympathetic and sympathetic damage: in addition to abnormal parasympathetic functions, finding in one or both of the sympathetic tests are abnormal.

Table 23. The scoring of the five Ewing tests as normal, borderline and abnormal results.

test	normal	borderline	abnormal
Heart rate response to valsalva maneuver	≥ 1.20	1.11-1.20	≤ 1.0
Heart rate variation during deep breathing	≥ 15 beat /minute	11-14 beats /minute	≤ 10 beat/minute
Immediate heart rate response to standing	≥ 1.04	1.01-1.03	≤ 1.00
Blood pressure response to standing (decrease)	≤ 10 mm mercury	11-29 mm mercury	≥ 30 mm mercury
Blood pressure response to sustained hand grip(increase)	≥ 16 mm mercury	11-15 mm mercury	≤ 10 mm mercury

BIBLIOGRAPHY

The following books are referred to in the text by the name of the author(s)

- 1-Afifi Adel. Bergman AR. Functional Neuroanatomy. 2nd edition 2005
McGraw-Hill, New York
- 2- Ropper AH. Samuels MA. Adams and Victor's Principles of neurology. 9th
edition 2009. McGraw-Hill, New York.
- 3- Bickerstaff ER, Spillane JE. Neurological examination in clinical practice. 6th
edition 1996. Blackwell Scientific Publication, Oxford. Ox, Mass.USA
- 4-Brazis PW, Masdeu JC, Biller J. Localization in clinical neurology. 5th edition,
Sep 2006. Lippincott Williams & Wilkins.
- 5-Ewing et al, Diagnosis and management of diabetic autonomic neuropathy-
Bri-Med.j.1982: 915-918.
- 6-Gupta K. 100 short cases for the MRCP. First edition 1983. Chapman and Hall
- 7-Haslett C, Chilver ER, Hunter JAA, Boon NA. Davidson's principles and
practice of medicine. 20th edition 2010. Churchill Livingstone
- 8-Hind CRK. Short cases for the MRCP (UK). Churchill Livingstone.
- 9-Patten J. Neurological differential diagnosis. 2nd edition 1998. Springer,
London.
- 10-Rohkamm R. Color Atlas of Neurology. 2nd edition 2004 Thieme Stuttgart.
New York.
- 11-Simon RP, Aminoff MJ, Greenberg DA (Eds). Clinical neurology. 6th Edition
2005, McGraw-Hill, USA.
- 12-Swash M, Mason S. Hutchison's clinical Methods. 21th Edition, 22 Oct
2001. London, W. B Saunders Ltd, London

Index

A

Abducent (6th) nerve, 66, 69
Absence of two point discrimination, 28
Acalculia, 22, 31
Accessory (11th) nerve, 111-114
Accommodation reaction, 61, 63, 64
Adie pupil, 63
Ageusia, 92
Agnosia
 Visual, 31
 Tactile, 31
 Auditory, 32
Agraphesthesia, 72
Agraphia, 25
Alexia, 22
Allesthesia, 28
Amnesia
 Causes, 8
 Features, 7
Amyopic crescent, 54
Analgesia, 150
Angular gyrus syndrome, 21
Anisocoria, 58, 61-65
Ankle
 Clonus, 137
 Jerk, 134
Anosmia, 39
 Lesions causing, 40
Aphasia, 19
 Agraphia, 25
 Alexia, 21
 Anomia, 24
 Broca's, 20
 Conductive, 21

Transcortical, 27

Wernicke's, 20

Apraxia, 33

 Constructional, 33

 Dressing, 34

 Ideational, 33

 Ideomotor, 33

Argyll-Robertson pupil, 64

Asomatognosia, 27

Astereognosia, 27

Ataxia, 145, 146

Ataxic respiration, 173

Athetosis, 124

Audiometry, 97

Avoiding response, 36

B

Babcock's sentence, 6

Babinski response, 142

Balint syndrome, 190

Battle sign, 170

Bells palsy, 91

Bells phenomenon, 90

Biceps jerk, 135

Bing's sign, 142

Bjerrum screen, 45

Blind spot, 43

Breathing

 Pattern in unconscious patient, 172, 173

Broca's aphasia, 20

Bruns's nystagmus, 81

Bulbar palsy, 108, 109

C

Caloric test, 100, 173, 183-5

Central neurogenic hyperventilation, 173

Cervical sympathetic paralysis, see Horne syndrome

Cherry red spot, 57, 171

Cheyne - Stokes respiration, 172, 173

Choroiditis, 57

Claw-hand, 128

Clonus, 137, 138

 Sustained, 138

 Unsustained, 183

Coma, 2, 170, 186

Comprehension to spoken language, 18

Conductive aphasia, 21

Confabulation, 8

Confrontation test, 43

Confusional state, 3, 8, 12

 Common causes, 12

 Drugs associated with, 13

Conjugate gaze palsy,

Consciousness

 Dissociation of, 3

 Level of, 1

 Turbidity of, 3

Constructional apraxia, 33, 34

Constructional tests, 33

Convergence-retraction nystagmus, 79

Coordination of movement, 142-146

Corneal reflex, 85, 86

Cranial nerves

 Accessory, 111-114

 Facial, 88-95

 Glossopharyngeal and vagus, 102-111

 Hypoglossal, 114-117

 Ocular, 57-81

 Olfactory, 38-41

 Optic, 41-57

Crossed- hemiparesis, 153

D

Deafness

 Causes, 98

 Localization of, 99

 Test of, 96, 97

Decerebrate posture, 179, 181, and 184

Decorticate posture, 179, 182, and 184

Delirium, 3

Dementia, 8-11

 Causes of, 9

 Minimental status examination, 10

 Pictures, 11

Dermatome, 147, 148

Diplopia, 73

 Causes, 66

 Methods of examination, 74

Disorientation, 12

Dolls head movement. 177, 178, 183-186

Dorellos canal, 66

Double vision, see diplopia,

Drowsiness, 2

Dysarthria, 104

 Test of, 104

 Types, 105-107

Disdiadochokinesia, 143

Dysgraphia, 25, 26

Dysmetria, 143

Deyssynergia, 143

E

Echolalia, 23

Edinger-wesphal nucleus, 62

Enophthalmos, 59

Exophthalmic ophthalmoplegia, 59

Extensor planter response, see Babinski sign.

F

Facial nerve, 88-94

Fasciculation, 121

Physiological, 121

Pathological, 121

Fields of vision see visual fields

Finger flexion test, 136

Finger-nose test, 143

Fundoscopy, 48-57

G

Gait, 157

Gag reflex, 105, 108, and 109

Gaze palsy,

Conjugate, 70

Disconjugate, 72

Glabellar tap reflex, 36

Glasgow coma scale, 5

Glossopharyngeal nerve, 102-

Gradenego syndrome, 96

H

Hands

Wasting of hands muscles, 120

Claw hands, 128

Hand (wrist drop), 128

Carpal tunnel syndrome,

Hearing loss, 96-99

Holmes-aide syndrome, 63

Horner syndrome, 59

Hyperacusis, 90

Hyperaesthesia, 151

Hyper-reflexia, 150

Hyper-tonia, 129

Hyperventilation, central neurogenic, 173

Hyperaesthesia, 151

Hypoalgesia, 150

Hypoglossal (12th) nerve, 115-117

Hypotonia, 130

I

Internuclear ophthalmoplegia, 72, 73

Increase intracranial pressure, see papilloedema

Involuntary movements, 124

J

Jargon aphasia, 20

Jaw jerk, 83, 84, 80

Jendrassik's maneuver, 137

Jerk

Ankle, 135

Biceps, 135

Jaw, 89

Knee, 136

Supinator, 136

Triceps, 136

Judgment and reasoning test, 15

K

Kernig's sign, 175

Kostenboum's sign, 52

Knee jerk, 136

Kosakoffs psychosis, 8

L

Language, 16

Methods of examination, 18, 19

Clinical varieties of disturbance, 16-26

Schematic approach, 26

Lateral spinothalamic tract, 141

Limbs,

Lower

Power testing, 133

- Reflexes testing, 136-138
- Tone testing, 129
- Upper
 - Power testing, 131-132
 - Reflexes testing 135-138
 - Tone testing, 128
- Lower motor neuron, 165
- Locked-in syndrome, 4
- M**
- Marcus Gunn pupil, 64
- Medical research council scale, 134
- Melkersson syndrome, 91
- Memory
 - Amnesia, 7
 - Dementia, 8
 - Test of, 6
- Meningeal irritation,
 - Brudzinski sign, 175
 - Signs of, 175, 176
- Minimal status examination, 10
- Muscular wasting, 118-121
 - Distal, 120
 - Proximal, 119
 - Small muscles of the hands, 120
- Myokymia, 124
- Myotomes, 149
- Medical research council, 132
- N**
- Naming, test of, 19
- Neck stiffness, 175
- Neologism, 18
- Nystagmus, 75-81
 - Cerebellar types, 80-81
 - Jerky, 76
 - Optokinetic, 81

- Pendular, 76
- Rotatory, 78
- Testing of, 76
- O**
- Ocular movement
 - In conscious person, 58
 - In unconscious person, 177-179
- Oculomotor (3rd) nerve, 57-68
- Olfactory (1st) nerve, 38-41
- Ophthalmoscopy, 49-51
- Oppenheim's sign, 142
- Optic atrophy, 51, 52
- Optic cup, 50
- Optic disc, 49
- Optic (2nd) nerve, 41-57
- Optic nerve head
 - Edema, 52, 53
 - Neuritis, 53
- Optic neuritis, 53
- Optokinetic nystagmus, 81
- Orientation, 12
- Orofacial apraxia, 33
- Otorrhea, 170
- P**
- Palmer grasps reflex, 51, and 52
- Palmo-mental reflex, 50
- Papilloedema, 52
- Paraphasia, 18
- Paratonia, 130
- Perimetry, 45
- Peripheral nerve lesions, 165-168
- Perseveration, 18
- Persistent vegetative state, 4
- Planter reflex
 - Normal response, 141

- Abnormal response, 142
- Position sense, 152
- Posture, abnormal, 128
- Power, muscle power, 131-133
- Proptosis, 60-61
- Pseudo athetosis, 124, 152
- Pseudo papilloedema, 49, 50
- Ptosis, 58-59
- Pupils
 - Abnormalities in conscious, 61-64
 - Abnormalities in comatose, 196-197
- Pyramidal system (UMNL)
 - Signs of, 162
 - Localization, 162, 163
 - Pictures, 164
- Pyramidal's syndrome, 72
- Q**
- Quadrantanopia
 - Lower, 46
 - Upper, 45
- Quadriplegia, 164
- R**
- Ramsay –Hunt syndrome, 90
- Reading
 - Test of, 19
 - Alexia, 22
- Reasoning and judgment, test of, 15
- Red-head pin test,
 - Assessment of blind spot, 43
 - Assessment of central field, 44
- Reflexes
 - Areflexia, 138
 - Babinski, response, 142
 - Clonus, 137
 - Grading, 138
 - Hyperreflexia, 139
 - Method of examination, 135
 - Primitive reflexes, 36
 - Superficial reflexes, 140,
- Respiration, patterns in comatose patients
 - Ataxic, 173
 - Cheyne-stokes, 172
- Retina
 - Arteriosclerosis, 54
 - Central artery occlusion
 - Central retinal vein occlusion
 - Exudates, 50
 - Hemorrhage, 55
 - Hypertensive retinopathy, 54
 - Phakomata, 56
 - Pigmentary abnormalities, 57
 - Tubercle, 50
- Retinopathy, hypertensive, 54
- Rhinorrhea, 170
- Rigidity, 130
 - Cogwheel, 130
 - Lead pipe,
- René, test, 96
- Romberg sign,
- S**
- Seesaw nystagmus, 79
- Sensation testing, 143
 - Dermatomes, 148
- Sensory inattention, 29
- Skew- eye deviation, 73
- Spasticity, 129
- Speech assessment, 104
 - Dysarthria types, 105-107
- Sternomastoids, test of, 113
 - Paralysis, 113, 114

Squint, 65

Sucking reflex, 36

Synkinesia, 94

T

Tactile sensation, 151

Taste, testing of, 89

Loss of, 92

Temperature, testing of, 150

Patterns of abnormal sensation, 154-155

Tendon reflexes, 153-140

Tinnitus, 99

Tone, 128-132

Tone-decay test, 97

Tonsillar- herniation,

Touch sensation, 151

Trapezius paralysis, 113, 114

Tremor, 124

Types of, 125

V

Vagus (10th) nerve, 102-111

Verbal comprehension, 18, 20-23

Vertigo, 98-101

Vestibulo-chochlear (8th) nerve, 96-

Vibration sense, 147, 151, 155, 157

Visual acuity, 41

Localization of visual loss, 42

Visual agnosia, 31

Visual fields, 42-47

Visual impairment, 42

Visual pathways, 46

W

Weakness,

Pattern of muscle weakness, 134

Clinical localization of neurological
weakness, 162-169

Weber test, 97

Wernicke's- korsakoff syndrome, 8

Wrist- drop, 134

Writing, Test of, 19

Inability to write (agraphia), 25